Volume 47 Supplement 5 October 2016 ISSN 0020-1383

ELSEVIER

Decade of Action for Road Safety 2011-2020
Supported by *Injury*

Official Journal of the Saudi Orthopaedic Association

Official Journal of the Australasian Trauma Society

AOTrauma

Italian Society of Orthopaedics & Traumatology

Gerhard Küntscher Society

Spanish Society of Orthopaedic Surgery and Traumatology (SECOT)

Turkish Orthopaedic Trauma Society

Groupe d'Etude en Traumatologie Ostéoarticulaire

Croatian Trauma Society

Brazilian Association of Orthopedic Trauma

Club Italiano Osteosintesti

European Society of Tissue Regeneration in Orthopaedics and Traumatology

Official Journal of the British Trauma Society

Injury

International Journal of the Care of the Injured

Abstracts of Osteosynthese International 2016
Gerhard Küntscher Society Annual Meeting

22–24 September 2016
Aschaffenburg, Germany

INJURY International Journal of the Care of the Injured

Official Journal of the British Trauma Society, the Australasian Trauma Society and the Saudi Orthopaedic Association in Trauma and affiliated with the Societa' Italiana Di Ortopedia e Traumatologia, The Gerhard Kuentscher Society, the Spanish Society of Orthopaedic Surgery and Traumatology (SECOT), the Turkish Orthopaedic Trauma Society, AOTrauma, the Group d'Etude en Traumatologie Ostéoarticulaire, the Croatian Trauma Society, the Brazilian Association of Orthopedic Trauma, the Trauma Society of India, the Club Italiano Dell'Osteosintesi (CIO) and the European Society of Tissue Regeneration in Orthopaedics and Trauma (ESTROT).

Abstracts of Osteosynthese International 2016
Gerhard Küntscher Society Annual Meeting

22–24 September 2016
Aschaffenburg, Germany

Funding body agreements and policies
Elsevier has established agreements and developed policies to allow authors whose articles appear in journals published by Elsevier, to comply with potential manuscript archiving requirements as specified as conditions of their grant awards. To learn more about existing agreements and policies please visit http://www.elsevier. com/fundingbodies

Advertising orders and enquiries can be sent to: **USA, Canada and South America**: Elsevier Inc., 360 Park Avenue South, New York, NY 10010-1710, USA; phone: (+1) (212) 633 3974. **Japan:** The Advertising Department, Elsevier K.K., 4F Higashi-Azabu, 1-Chome Bldg, 1-9-15 Higashi-Azabu, Minato-ku, Tokyo 106-0044, Japan; phone: (+81) (3) 5561 5037; fax: (+81) (3) 5561 5047; e-mail: jp.info@elsevier.com. **Europe and ROW:** Commercial Sales Department, Elsevier Ltd., The Boulevard, Langford Lane, Kidlington, Oxford OX5 1GB, UK; phone: (+44) 1865 843016; fax: (+44) 1865 843976; e-mail: media@elsevier.com

Commercial Reprint Orders and enquiries can be sent to: Elizabeth Drayton at e.drayton@elsevier.com

USA mailing notice: *Injury* (ISSN 0020-1383) is published monthly by Elsevier Ltd. (P.O. Box 211, 1000 AE Amsterdam, The Netherlands). Periodicals postage paid at Jamaica, NY 11431 and additional mailing offices.
USA POSTMASTER: Send change of address to *Injury*, Elsevier Customer Service Department, 3251 Riverport Lane, Maryland Heights, MO 63043, USA.
AIRFREIGHT AND MAILING in USA by Air Business Ltd., c/o Worldnet Shipping Inc., 156-15, 146th Avenue, 2nd Floor, Jamaica, NY 11434, USA.

♾ The paper used in this publication meets the requirements of ANSI/NISO Z 39.48–1992 (Permanence of Paper)

INJURY

International Journal of the Care of the Injured

Author inquiries: You can track your submitted article at http://www.elsevier.com/track-submission. You can track your accepted article at http://www.elsevier.com/trackarticle. You are also welcome to contact Customer Support via http://support.elsevier.com

For a full and complete Guide for Authors, please go to:
http://www.elsevier.com/locate/injury.

Publication information: *Injury* (ISSN 0020-1383). For 2016, volume 47 (12 issues) is scheduled for publication. Subscription prices are available upon request from the Publisher or from the Elsevier Customer Service Department nearest you or from this journal's website (http://www.elsevier.com/locate/injury). Further information is available on this journal and other Elsevier products through Elsevier's website (http://www.elsevier.com). Subscriptions are accepted on a prepaid basis only and are entered on a calendar year basis. Issues are sent by standard mail (surface within Europe, air delivery outside Europe). Priority rates are available upon request. Claims for missing issues should be made within six months of the date of dispatch.
Orders, claims, and journal enquiries: please contact the Elsevier Customer Service Department nearest you: **St. Louis:** Elsevier Customer Service Department, 3251 Riverport Lane, Maryland Heights, MO 63043, USA; phone: (800) 6542452 [toll free within the USA]; (+1) (314) 4478871 [outside the USA]; fax: (+1) (314) 4478029; e-mail: JournalsCustomerService-usa@elsevier.com **Oxford:** Elsevier Customer Service Department, The Boulevard, Langford Lane, Kidlington OX5 1GB, UK; phone: (+44) (1865) 843434; fax: (+44) (1865) 843970; e-mail: JournalsCustomerServiceEMEA@elsevier.com **Tokyo:** Elsevier Customer Service Department, 4F Higashi-Azabu, 1-Chome Bldg, 1-9-15 Higashi-Azabu, Minato-ku, Tokyo 106-0044, Japan; phone: (+81) (3) 5561 5037; fax: (+81) (3) 5561 5047; e-mail: JournalsCustomerService Japan@elsevier.com **Singapore:** Elsevier Customer Service Department, 3 Killiney Road, #08-01 Winsland House I, Singapore 239519; phone: (+65) 63490222; fax: (+65) 67331510; e-mail: JournalsCustomerServiceAPAC@elsevier.com

Injury has no page charges.

Printed by Henry Ling Ltd., The Dorset Press, Dorchester, UK

Dear Colleagues,
Dear friends of Osteosynthese International of Gerhard Küntscher Society,

The Küntscher Society is an internationally active society that originated from a group of enthusiastic and keen Küntscher students dedicated to fracture treatment with intramedullary nailing. Today Osteosynthesis international is promoting all forms of osteosynthesis and fracture care. Due to the increasingly aging population in industrial countries on the one hand and the growing mobility and physical activity of younger people on the other hand, the number of patients with bone fractures has risen continuously. New questions regarding anchoring and load stability together with the development of adequate implants for the individual skeletal regions have been moved into the center of attention.

In case of shaft fractures locking nail osteosynthesis is by far the most common procedure, whilst for fractures of themeta- and epiphyseal area the trend appears to go towards alternative treatment. Type A fractures and simple slightly displaced C fractures are usually treated with anatomically adapted intramedullary nails, multi-fragment fractures are commonly treated using locking plates and highly complex fractures using endoprosthesis.

The importance of treatment choice for the different skeletal regions is still subject for discussions. For this reason, we chose as main topic of the 2016 congress to analyse and discuss today's therapeutic concepts and techniques for all long bones and other anatomic areas. Eight scientific meetings and eight workshops are on the agenda.

It is our particular intention to pass on this knowledge to the following generation of trauma and orthopaedic surgeons. This is why we also like to encourage doctors in training to participate in this congress since it offers a compact form of knowledge acquisition.

Physiotherapy and rehabilitation professionals are highly welcome to our congress.

I therefore invite you to come to Aschaffenburg on 22–24 September 2016. The city is rich in history and culture and used to be former summer residence for Bishops of Mainz. Frankfurt Airport is only 50km away and easy to get to.

Prof Dr. Dr. h.c. Wilhelm Friedl
Congress president 2016

Dr. Jan Verbruggen
President Gerhard Küntscher Society (GKS)

INJURY International Journal of the Care of the Injured

Official Journal of the British Trauma Society, the Australasian Trauma Society and the Saudi Orthopaedic Association in Trauma and affiliated with the Societa' Italiana Di Ortopedia e Traumatologia, The Gerhard Kuentscher Society, the Spanish Society of Orthopaedic Surgery and Traumatology (SECOT), the Turkish Orthopaedic Trauma Society, AOTrauma, the Group d'Etude en Traumatologie Ostéoarticulaire, the Croatian Trauma Society, the Brazilian Association of Orthopedic Trauma, the Trauma Society of India, the Club Italiano Dell'Osteosintesi (CIO) and the European Society of Tissue Regeneration in Orthopaedics and Trauma (ESTROT).

Volume 47, Supplement 5, October 2016

Contents

Injury, Int. J. Care Injured (2016) **47**(S5), S1–S38

Contents lists available at SciVerse ScienceDirect

Injury

journal homepage: www.elsevier.com/locate/injury

Session I: Nail vs. plate vs. prosthesis: tibia

OS1-01
How choice of implant used for fracture fixation of long bones affects fracture healing? A new fracture-healing matrix is proposed

R. Varma[1]. [1]*King's College Hospital, Consultant Orthopaedic Surgeon, London, United Kingdom*

Introduction: A fracture-healing matrix is proposed in relation to choosing the mode of surgical fixation (ORIF/IM Nailing/External or Internal Fixator) to stabilize fractures of long bones. The four elements of this matrix include 1. Fracture personality 2. Strain at fracture site after proposed surgical fixation (Zero Strain/Optimal Strain/Excessive Strain). 3. Fracture/Implant Composite Early (bending or load to failure strength) & Late (fatigue) Strength. 4. Time for limb to return to function (Return to work/life for patient).
Description: The fracture healing by callus formation is dependent on the movement or strain at the fracture site, which itself is dependent on the fracture geometry, fracture reduction and rigidity of the fixation achieved. So when open anatomical reduction of the fracture is carried out with rigid internal fixation the strain at the fracture site is approaching zero and the normal fracture healing process of callus formation is aborted. In this situation the healing takes place by so called primary or direct bone healing which essentially is bone-remodeling process. When far-far fixation is used as in IM Nailing optimum strain is achieved at fracture site leading abundant callus formation. With external fixator and locked plating, when near – far fixation is used, the strain at fracture site is reduced leading to prolonged fracture healing time. With rigid internal fixation, fracture, callus formation is inhibited and the fixation must maintain its strength over a prolonged period of time. The fixation fails early when the physiological forces of activities of daily living overwhelm the bending strength or load to failure strength of the fixation. It fails late with fatigue failure of the implant.
Discussion: These points are explained in greater detail using illustrative cases.

OS1-02
Principles of fracture fixation in osteoporotic long bone fractures

R. Varma[1]. [1]*King's College Hospital, Consultant Orthopaedic Surgeon, London, United Kingdom*

Introduction: There are two major challenges in surgical fixation of osteoporotic fractures. The first is that poor bone quality leads to poor implant fracture composite strength and second is the need for early return to function of the injured limb. Both of these conflicting demands lead to early implant fixation failure and if the construct is made strong enough to withstand early deforming forces then it becomes too rigid and leads to impaired callus formation and delayed fracture healing leading to increased incidence of late or fatigue failure of the implant.
Description: Open reduction with rigid internal fixation is not always possible, as the poor quality of bone does not allow for rigid screw bone interface. IM nailing is the treatment of choice for shaft long bone fractures but the problem areas are the metaphyseal fracture of the long bones. The choice is between the locked plating and extended indications of the IM nailing. The difficulty with IM nailing is high incidence of malunion. With locked nailing however the difficulty arises in getting optimum stain at the fracture site as to get adequate fixation in osteoporotic bone more screws are needed making the ultimate fixation rigid and thus less conducive to callus formation.
Discussion: Various strategies are discussed using case examples to recommend use of IM nailing and locked plating techniques to overcome these difficulties for proximal femoral, distal femoral, proximal tibial and distal tibial fractures in osteoporotic patients.

OS1-03
Management of musculoskeletal injuries secondary to gunshot

R. Fox[1], R.D. Zura[1]. [1]*Louisiana State University Health Science Center, New Orleans, United States*

In the United States, approximately 84,000 non-fatal gunshot wounds occur annually. Experience within an urban trauma center indicates that approximately 59% of patients sustained gunshot required orthopedic consultation. These injuries present with considerable variability based on those specific structures damaged by the projectile and ballistic fragments. Each injury dictates a treatment algorithms to address each specific musculoskeletal and/or neurovascular injuries. Occasionally, this necessitates a multi-specialty team approach.
We present a literature-based approach to civilian gunshot injuries combined with our experience in a Level I urban trauma center. Our aim with this presentation is to provide the surgeon with adequate knowledge related to gunshot injuries to interpret the patient's presentation and administer evidence-based clinical decisions.
Our focus is on the pertinent basics for civilian gun ballistics, with regards to projectile velocity and caliber, as well as the resulting clinical manifestations of impact. Through review of existing current literature we discuss those gunshot injuries for which we have defined treatment protocols. Furthermore, we will discuss in brief those injuries for which little consensus exists to highlight those areas where further research will improve surgeons' treatment of such injuries.

OS1-04
Tibial head depression fractures in elderly: a biomechanical study of different treatment options

S. Hoelscher-Doht[1], M.C. Jordan[1], L.-C. Faerber[1], H. Jansen[1], S.P. Frey[1], T. Blunk[1], R.H. Meffert[1]. [1]*Department for Trauma, Hand, Plastic and Reconstructive Surgery, University Clinics of Würzburg, Würzburg, Germany*

Question: Tibial head fractures account for 10% of all fractures in the elderly. Due to metaphyseal bone loss, depression fractures frequently occur and need to be treated operatively. After reduction of the depressed articular fracture fragment, a metaphyseal bone defect remains. Filling the defect with an autologous crest bone graft is not possible because of fatty degeneration of the crest bone. Instead,

bone substitutes are used. Following operative treatment, the postoperative regime includes partial weight bearing of 15–20 kg for 3 months. Older patients, however, often do not follow this regime, resulting in a secondary subsidence of the depressed articular fracture fragment due to excessive weight bearing. Therefore, the aim of this biomechanical study was to systematically analyse different options of osteosyntheses alone and in combination with a commonly used bone substitute for treating tibial head depression fractures.

Group	Osteosynthesis	Bone substitute
1	2 Screws (A)	---
2	2 Screws	ChronOs
3	4 Screws (B)	---
4	4 Screws	ChronOs
5	Buttress Plate (C)	---
6	Buttress Plate	ChronOs
7	---	ChronOs

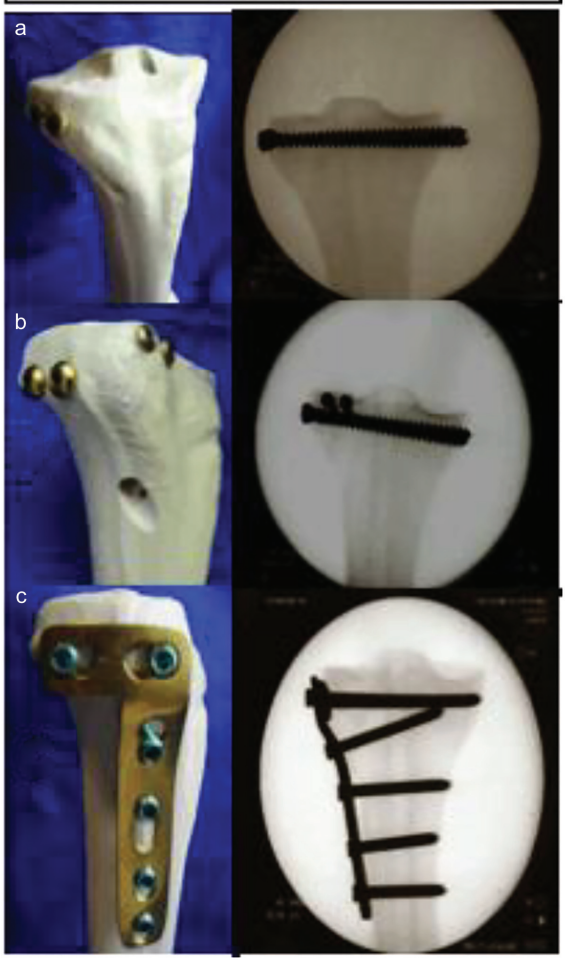

Figure 1: Experimental groups: Type of osteosynthesis ((a) 2 screws, (b) 4 screws in the jail technique, and (c) lateral buttress plate) alone or in combination with bone substitute.

Materials and Methods: Lateral tibial head depression fractures were created in Synbones (SYNBONE®, Switzerland) in a fracture model. After reduction, the fractures were stabilized with 7 different treatment options of an osteosynthesis alone or in combination with a bone substitute (Figure 1). Two screws, 4 screws using the jail technique, and a lateral buttress plate were investigated. As bone substitute, the common clinically used calcium phosphate cement ChronOS™ Inject was applied. Cyclic testing was performed using 500 N for 5,000 cycles, simulating half weight bearing of a 90 kg patient after operative treatment of tibial head depression fractures. Displacement of the articular fracture fragment during cyclic loading (mm), the stiffness (N/mm) and the maximum load (N) in load-to-failure tests were measured.

Results: The plate osteosynthesis in combination with bone substitute revealed a higher stiffness compared to all the other groups ($p < 0.01$). The 2 screw osteosynthesis exhibited a lower maximum load compared to the groups with 4 screws, with ($p < 0.01$) and without bone substitute ($p = 0.01$), and compared to the plate osteosynthesis ($p < 0.01$). There were no significant differences for the maximum load between the groups with 4 screws and the plate osteosynthesis (all $p = 1.0$). The displacement for the plate osteosynthesis was significant higher compared to the 2 screws ($p = 0.01$), the 2 screws with bone substitute ($p < 0.01$) and the 4 screws ($p = 0.01$). However, in combination with bone substitute, the plate osteosynthesis revealed a lower displacement than the plate alone ($p < 0.01$).

Conclusions: Tibial head depression fractures are at risk of a secondary loss of reduction after an operative treatment, especially when a partial weight bearing cannot be followed. A 4 screw osteosynthesis revealed an equivalent stability under maximal loading and under cyclic loading even a lower displacement of the articular fracture fragment compared to a plate osteosynthesis. However, from a biomechanical point of view, even under higher loading conditions than the orthopaedic surgeon demanded, a 4 screw osteosynthesis in combination with bone substitute is the adequate treatment for tibial head depression fractures.

OS1-05

Simultaneous nailing of the ipsilateral femur and tibia fractures: the up down nail

R. Auer[1], D. Seligson[1], J. Riehl[1]. [1]*University of Louisville, Madison, United States*

Question: Ipsilateral fractures of the femur and tibia are commonly referred to as a floating knee injury. These injuries are typically associated with high energy mechanisms and considerable complications. With the availability of intramedullary nails and the increased attention on damage control orthopaedics, further evidence and evaluation of current techniques is needed. The purpose of this study is to evaluate early perioperative outcomes, morbidity, associated injuries, and treatments across the spectrum of floating knee injuries including simultaneous nailing of tibia and femur fractures.

Methods: A retrospective study of our hospital's trauma database was used to evaluate patients with ipsilateral femur and tibia fractures. Patients who had sustained a fracture of both the tibia and the femur were identified and included. Fractures of the femoral head, neck, peritrochanteric, pilon and ankle were not considered as floating knee injuries and were excluded. Imaging studies were reviewed to determine the OTA/AO and Fraser classification for each fracture pattern.

Results: Sixty-three (0.07%) patients were treated for 66 floating knee injuries. Seventy-three percent were male with an average age of 38.5 years old. Motor vehicle and motorcycle accidents represented 77.2% of the mechanisms of injury. There were 5 hospital deaths and 3 amputations. The average floating knee patient spent 20 days in the hospital with nearly 8 of those days in the intensive care unit and 4

days requiring ventilator assistance. The average Injury Severity Score was 21, Fraser type IIB was significantly higher (ISS 30, $p < 0.05$) and Fraser type I the lowest (ISS 20). The average Fraser type I was significantly lower (32 years, $p < 0.007$) and Fraser type IIC having the highest age (45 years).
The results of Fraser classification were: type I 41%, type IIA 30%, type IIB 12%, type IIC 17%. Intramedullary fixation was used as definitive treatment for 64.7% of femur fractures and 45.1% of tibia fractures. A single incision for the intramedullary nailing of both fractures was used in 17 patients, 12 at the same surgery. Complications included one perioperative death, one non-union and one malunion revision surgery.
Significant complications occurred in the other floating knee patients including three amputation and five hospital deaths. Other significant complications occurred including acute compartment syndrome, nonunion, deep infection, and peri-implant fracture.
Conclusions: Floating knee injuries, frequently associated with concomitant injuries and high energy trauma, represent a unique combination of fractures. In our study population Fraser type I patients were significantly younger than Type II patients and had a lower ISS. Fraser Type IIB injuries occurred in older patients and were associated with a significantly higher ISS. Because of the high energy associated with these fractures, external fixation was employed more frequently. At our institution, definitive intramedullary nailing through a single incision was useful treatment option for patients with Type 1 floating knee injuries.
Our cohort of patients had multiple complications postoperatively including non-union, malunion, infections and peri-implant fractures. Floating knee injuries remain a life and limb threatening injury that is associated with multiple complications and a prolonged recovery. Damage control orthopaedics with external fixation is appropriate for initial management.

OS1-06
Intramedullary nailing of tibial fractures: results and complications

G. Tomoaia[1], C. Bardas[1], H. Benea[1], M. Paiusan[1], D. Oltean[1], Z. Gabri[1], R. Tomoaia[1], C. Dan[1]. [1]*Orthopedics and Traumatology, UMF "Iuliu Hatieganu", Cluj-Napoca, Romania*

Introduction: Tibial fractures are one of the most serious long bone fractures, due to their potential for malunion, nonunion and long-term dysfunction, as well as their propensity for open injury. Intramedullary nailing represents the gold standard treatment for displaced and closed fractures or some types of open diaphyseal fractures.
Objectives: The aim of this retrospective clinical study was to analyze the functional outcome of patients with tibial shaft fractures, treated with conventional intramedullary nails.
Materials and Methods: The study included 91 patients (62 males and 29 females) with tibial shaft fractures, hospitalized and surgically treated between January 2013 and December 2015 in the Orthopaedics and Traumatology Clinic of Cluj-Napoca, using intramedullary nailing as a definitive fixation treatment. The mean age of male patients was 38 (range 18–89 years) and for women 44 (range 26–90 years).
Results: We have found 93 fractures in 91 patients that were treated with intramedullary nailing. Twenty-one percent of patients (6% females and 15% males) had a second intervention for dynamization of intramedullary nail, procedure that led to shortening of recovery time in this group in contrast with the rest of cases. Only 3 patients had surgery for complications related to intramedullary nailing.
Conclusion: The study showed that intramedullary nailing represent a very good option for tibial fractures treatment, and the dynamization of the nail improves the healing and recovery of patients with this type of fracture.

OS1-08
The treatment of the leg fractures using internal medullar nail implants. Retrospective study

D. Calin[1], D. Grecu[1], A. Grecu[1], C. Prica[1], M. Sarbu[1], W. Shaban[1]. [1]*Orthopedics-Traumatology, Emergency Hospital Craiova, Craiova, Romania*

Purpose: The present paper represents the experience of our clinics regarding the treatment of leg fractures using internal medullar nails – Kuntscher nails and locking nails.
Materials and Methods: We reviewed 178 patients in our clinics during 01/01/2014–31/01/2016 treated by bone synthesis with locked nails and Kuntscher's nails. We used 123 Kuntscher's nails and 55 locked nails. We used the Kuntscher′s nail in simple fractures in 1/3 middle legs. In the 1/3 inferior leg fractures (>5 cm from to the ankle) and 1/3 upper leg fractures (>5 cm from the knee) we used locked nails. In the multi fragmentary fractures we used static locked nails, that were dinamised at 8 weeks after surgery.
In Kuntscher's we also used external plaster immobilization for 8–9 weeks, with 4 weeks of above knee cast followed by other 4 weeks of plaster immobilization below knee cast.
For locked nails, 4 days after the surgery, the patients started the rehabilitation. They were allowed to walk, without walking on the injured foot. After 10 weeks they were allowed to walk on the injured foot, with partially weight bearing –5 kilos.
For Kuntscher's nails, 4 days after the surgery, the patients started the rehabilitation. They were allowed to walk, without walking on the injured foot. After 12 weeks they were allowed to walk on the injured foot, partially weight bearing –5 kilos maximum.
The patients had an X-ray examination (F+P). The average anticlotting therapy for the locking nails was for 30 days and in the Kuntscher nails 80–85 days.
Results: The rehabilitation was shorter on the locked nails treated patients, with a lower complication rate, especially vascular complication. After 10 weeks they were allowed to walk on the injured foot, partially weight bearing –5 kilos.
The Kuntscher's nail bone synthesis has a higher rate of vascular complications that can make the recovery heavier or even stop the fully rehabilitation of the patients.
The complete recovery with walking completely on the foot was in 17–22 weeks for locked nails compared to 20–24 weeks for Kuntscher's nails.
Complications: DVT, late post thrombotic syndrome, chronic edema were observed more frequently in the Kuntscher nail patients.
Conclusions: Even treatment with K nail is cheaper, total cost, due to longer recovery period is higher.

Session II: Nail vs. plate vs. prosthesis: femur

OS2-09
The clinical results of the Dynamic Locking Blade Plate in the fixation of undisplaced and displaced femoral neck fractures

A. van Walsum[1], W. Roerdink[2], J. Vroemen[3], H. Janzing[4], T. Winkelhorst[5]. [1]*Trauma Surgery, MST, Enschede, Netherlands,* [2]*Trauma Surgery, Deventer Ziekenhuis, Deventer, Netherlands,* [3]*Trauma Surgery, Amphia Ziekenhuis, Breda, Netherlands,* [4]*Trauma Surgery, VieCuri Medical Centre, Venlo, Netherlands,* [5]*Trauma Surgery, Canisius Wilhelmina Ziekenhuis, Nijmegen, Netherlands*

Question: The osteosynthesis of femoral neck fractures results in high failure rates, which averages 11% for the undisplaced and 35% for the displaced fractures [1,2]. The question is: what are the possible implant related factors in this high failure rate and can we make a better implant? Based on the biology of this specific fracture it is postulated that only when the anatomical reduction is secured by stable internal fixation, revascularization of the femoral head can take place and the fracture can heal by primary osteonal reconstruction. The combination of an anatomical reduction and a low volume, dynamic implant, providing angular and rotational stability seems to be crucial factors in the treatment of intracapsular hip fractures. This assumption formed the starting point for the development of the Dynamic Locking Blade Plate (DLBP) [3] (Figure 1).

Material and Methods: In a multicenter cohort study on the clinical results of the DLBP 405 patients were included with a follow up of at least one year. The results were analyzed for the younger and elderly patients and for undisplaced and displaced FNF. Failure in fracture healing due to non-union, avascular necrosis or implant failure was the primary outcome measurer.

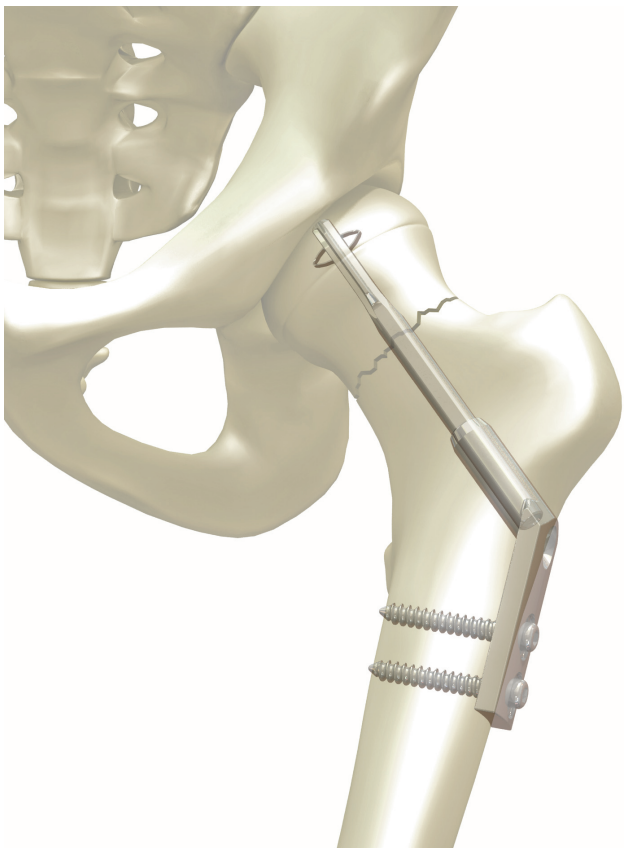

Figure 1: Illustration of the DLBP.

Results: In the younger age group (≤60 yrs) the failure rate was 2% for the undisplaced FNF and 14% for the displaced fractures. In the elderly age group (>60 yrs) the failure rate for the undisplaced FNF was 7% and the failure rate for the displaced fractures 19% [Table 1].

Conclusion: It is hypothesized that the device used to fix the femoral neck fracture must be a low volume, axial-dynamic implant providing angular- and rotational stability. The DLBP is developed according these characteristics. The results of this multicenter study compare favorably with the results of implants currently used and supports further clinical studies.

Table 1
Clinical results of the DLBP

Failure rate n = 405	Un-displaced n = 172	Displaced n = 233
≤60 yr (52) n = 159	2% n = 52	14% n = 107
>60 yr (73) n = 246	7% n = 120	19% n = 126

References

[1] Conn KS, Parker MJ. Undisplaced intracapsular hip fracture: results of internal fixation in 375 patients. *Clin Orthop Relat R*. 2004;421:249–54.

[2] Bhandari M, Devereaux PJ, Swiontkowski MF, Tornetta P 3rd, Obremskey W, Koval KJ, Nork S, Sprague S, Schemitsch EH, Guyatt GH. Internal fixation compared with arthroplasty for displaced fractures of the femoral neck. A meta-analysis. *J Bone Joint Surg Am*. 2003;85-A:1673–81.

[3] Roerdink WH, Aalsma AMM, Nijenbanning G, van Walsum AD. The dynamic locking blade plate, a new implant for intracapsular hip fractures: Biomechanical comparison with the sliding hip screw and the Twin Hook. *Injury*. 2009;40(3):283–7.

OS2-10

Blade type nail designs cause more varus collaps than screw type nails in the treatment of elderly trochanteric fractures

M.C. Okkaoglu[1], H. Sesen[2], I. Demirkale[2], M. Ozdemir[2], Y. Okkaoglu[3], M. Altay[2]. [1]*Orthopaedics and Traumatology, Yozgat Sarikaya State Hospital, Ankara, Turkey,* [2]*Orthopaedics and Traumatology, Ankara Kecioren Research and Training Hospital, Ankara, Turkey,* [3]*Statistics, Ankara University, Ankara, Turkey*

Introduction: Blade and screw type nail designs are widely used in the treatment of trochanteric fractures. Although, blade designs were put as last generation nails on the market, it remains unclear which design has better clinical and radiographic outcomes.

Methods: This study comprised 101 patients with trochanteric fractures treated with either proximal femoral nail antirotation (PFNA) as blade type nail, or Peritrochanteric nail (PTN) as screw type nail for a minimum of 6 months. We assessed comorbidities, fracture type pre-operatively, operation time, blood loss, reduction quality, tip apex distance intra and post operatively, medical and mechanical complications, partial, full weight bearing time, Harris hip scores and Short form 36 scores and mortality during follow up period.

Results: There was no significant difference in the operation time, blood loss, total mechanical or medical complications, partial, full weight bearing time, mortality rate, and Harris Hip scores of PTN or PFNA groups. Lateral migration and varus collaps rates of patients treated with PFNA were significantly higher than patients' treated with PTN. However particular SF 36 scores of PFNA group were significantly higher than PTN group.

Conclusion: Blade type nail designs caused more varus collaps than screw type nails in the treatment of elderly trochanteric fractures, however these radiographic complications didn't influence on clinical outcomes of patients.

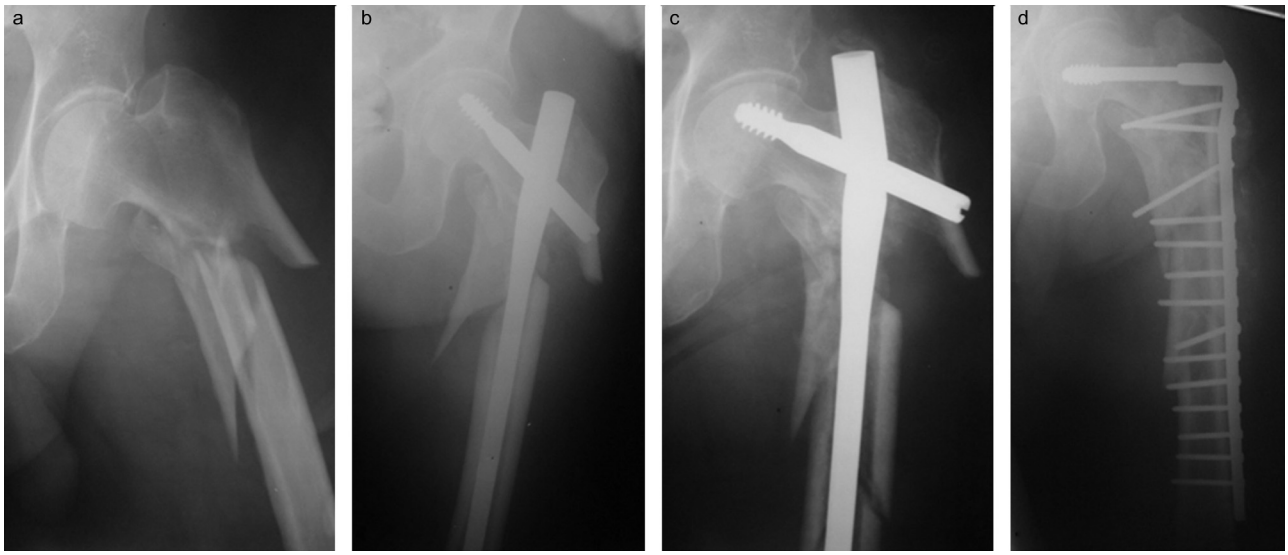

Figure 1: (abstract: OS2-11) Preop (A) and Postop AP radiographs of a subtrochanteric fracture Seinsheimer IV of left femur treated with LTGN. Reduction considered as poor. 4m postop AP view revealed breakage of the nail (C) which revised with a DCS (D) with good results.

OS2-11

Subtrochanteric femoral fractures treated with the Long Gamma3® nail: a historical control case study versus long trochanteric Gamma nail®

D. Georgiannos[1], M. Savvidis[1], V. Lampridis[1], I. Bisbinas[1], D. Kapoutsis[1], A. Konstandinidis[1], G. Gkouvas[1]. [1]*1st Orth. Dept., 424 General Military Hospital, Thessaloniki, Greece*

Question: Gamma nail was developed for the treatment of subtrochanteric hip fractures. Despite its advantages over extramedullary devices, gamma nail has been historically related to significant complications (implant breakage, femoral fractures at the tip of the nail). There is limited data to determine if the rate of these complications was minimized by using a new design of the gamma nail. Therefore we performed a case control study between the long gamma3 nail (LG3N) and the long trochanteric gamma nail (LTGN) to assess if: (1) the complication rate in the treatment of subtrochanteric fractures using the LG3N was lower than the one using the LTGN; (2) the reoperation rate was lower after using the LG3N.

Hypothesis: The complication rate after fixation of subtrochanteric fracture of the femur is lower with LG3N than with the LTGN.

Patients and Methods: This study prospectively recorded the intra- and postoperative complications of 75 patients with subtrochanteric fractures treated with the LG3N and compared them with those of ahistorical cohort of 83 patients treated with the LTGN. The two groups were matched regarding age, gender and fracture type. Patients with open, pathological, or impending fractures were excluded.

Results: Intraoperative complications in the LG3N group were lower (4 cases, 5.3%) compared with those in the LTGN group (9 cases, 10.8%; $p = 0.04$). The major intraoperative complication encountered with the use of LTGN was fracture of the femur in 3 cases. We encountered in total 9 postoperative complications in LG3N (12%) and 20 in group LTGN (24%). The most frequent complication in both groups was the cutout of the lag screw (3 cases in LG3N and 7 cases in LTGN group). The overall reoperation rate was higher in LTGN group (20.4% vs 10.6%; $p = 0.03$).

Conclusion: As a result of the improvement of its mechanical characteristics, LG3N has proved a safe and efficient implant for the treatment of subtochanteric fractures. The new design seems superior to previous generation, giving promising outcomes, reduced mechanical complication rates, and reduced reoperation rate.

Level of Evidence: Level III – case controlled study.

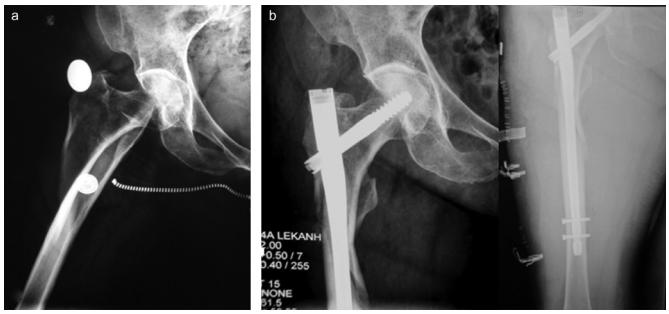

Figure 2: Right femoral subtrochanteric fracture Seinsheimer III (A) treated with LG3N (B).

OS2-12

Rotation instability and micro-movements are independent prognosis factors for the failure rate of dislocated medial femoral neck fractures

A. Alias-Petralanda[1]. [1]*Klinikum Aschaffenburg, Aschaffenburg, Germany*

Question: The instability of the fracture is an important factor for high failure rate of the osteosynthesis in medial femoral fractures. The micro-movements allowed with this instability are an independent factor from osteoporosis, disturbed blood supply and high biomechanical load. Rotation and movement stability, bone compression and minimized cut out risk are achieved with an I-beam implant.

Methods: A group of 93 patients with dislocated medial femoral neck fractures (Garden III–IV) were treated between 1982 and 1992 with 3 to 4 screw fixation (49% of them were reexamined after 10 years). In a second group, 83 patients with the same fracture types were treated with the gliding nail (GN) between 1999 and 2005. The GN is an intramedullary implant with a gliding femur neck component with a rotation stable I-beam profile. All patients were reexamined in 2006.
Results: In the screw fixation group, 29% of the patients had undergone a total hip replacement surgery. In the gliding nail treated patients, 10.4%. The severe offset loss (due to micro-movements with bone resorption) in the screw group was not seen in the GN group so that the device is used now also in cases with pseudoarthosis after screw fixation.
Conclusions: The rate of complications after medial femoral neck fractures is only in part dependent from the blood supply disruption. The minimized cut out risk, the avoided micro-movements and the rotation stability of the GN allows a relevant reduction of local complication rates as well as secondary hip replacement surgery.
Cut out and pseudoarthrosis are reduced dramatically. The datas are supported by our experimental test regarding the cut out risk.

OS2-13
Cut out rates in trochanteric fracture nailing can be reduced by the I-Beam profile of the femoral neck component of the gliding nail (GN)

T. Arnold[1], W. Friedl[1]. [1]*Klinikum Aschaffenburg, CK II, Aschaffenburg, Germany*

Question: Due to osteoporosis in the elderly and the high mechanical load of the proximal femur any bone-implant interface needs to provide the maximally possible stability. Cut out rates of 5–8% for the gamma nail, 10% for the PFN, 2–19% for the DHS and 5% for the PFNA have been reported. Therefore Cement augmentation for the PFNA has been introduced.
Methods: In experimental tests in sawbone and in paired human cadaver femur, alternating load tests were performed for the GN the Gamma Nail and the PFN. Also 501 consecutive patients with trochanteric fractures were treated with GN Osteosynthesis in a single trauma center form 1996–2001. 23 surgeons performed the Operation, of which 95% were within the first 36 h after Trauma. All were allowed immediate full weight bearing. Reexamination was performed at minimally 6 months.
Results: The highest stability in experimental tests was given by the I-Beam Blade of the GN. The risk of cut out was reduced by 50% compared to the single screw system of the Gamma Nail and 75% compared to the PFN. In the clinical group, no cut out occurred, Migration of the blade was seen in 3 Patients (0.6%) total implant related revision rate was 2.5%, Hematomas occurred in 2.5%. General complications such as urinary infection, pneumonia, cardiac and neurological complication rates were as high as 28.5%. Hospital mortality rate was 3.95% and highly dependent on systemic complication rate. Late complications occurred in 3.3% of patients and the 3 Month mortality rate was 14.3%.
Conclusions: The I-Beam profile of the GN neck component improves the stability of the bone implant interface thus decreasing the risk of cut out and allowing immediate full weight bearing. This probably is due to the higher contact surface of the blade, the rotational stability of the neck component and the impaction of bone while insertion is performed.

OS2-14
Nonunion and unplanned reoperation rates in adult proximal femoral fracture: a meta-analysis

R. Nomides[1], R. Zura[2], R.G. Steen[3]. [1]*Department of Orthopaedics, Duke University Medical Center, Durham, United States,* [2]*Department of Orthopaedics, LSU Health Science Center, New Orleans, United States,* [3]*Bioventus LLC, Durham, United States*

Introduction: Nonunion is a serious complication of proximal femoral fracture fixation. However, the surgical and patient factors that impact the rate of nonunion are poorly understood. We hypothesize that certain fracture types, methods of fixation, and patient characteristics influence the rate of nonunion and other serious complications requiring reoperation. Objectives: The aim of this meta-analysis was to characterize rate of nonunion in adult proximal femoral fractures after primary fixation and to determine the rate of unplanned reoperation after index fracture.
Materials and Methods: A literature search was performed using PubMed, Embase, and the Cochrane Review system. Inclusion criteria included studies with >20 proximal femoral fractures in patients 18 years old and older who were treated surgically. Pathologic fractures, revision surgeries, and arthroplasty were excluded. Study outcomes were uncomplicated healing, nonunions and all other causes of unplanned reoperation.
Results: A total of 220 studies examining 25,253 patients with 25,342 fractures were included in the meta-analysis (Table 1). Of these, 18,922 fractures were extracapsular and 6,420 fractures were intracapsular. Patients with extracapsular fractures were significantly older than patients with intracapsular fractures ($p < 0.00001$), with mean ages of 75.3 and 67.8 years old, respectively. Complications were higher in patients with intracapsular fractures ($p < 0.0001$); 11.1% had a nonunion and 8.2% required unplanned reoperations for other complications, resulting in uncomplicated healing in only 80.7% of intracapsular fractures. In contrast, 0.8% of patients with extracapsular fractures had nonunion and 4.6% had unplanned reoperations for other complications, resulting in uncomplicated healing in 94.6% of extracapsular fractures. The use of a nail for extracapsular fractures lead to a nonunion rate of 0.7% and an overall reoperation rate of 5.2%. Similarly, the use of a plate for extracapsular fractures resulted in a 0.9% nonunion rate and a 5.5% overall reoperation. Plates and neck based fixation (multiple cancellous screws for example) were the major methods of fixation for intracapsular fractures. Plates had a 5.7% nonunion rate whereas neck based fixation resulted in a 12.6% nonunion rate ($p < 0.01$). Although overall healing rates for each fixation method have changed greatly over time (Figure 1), nailed fractures demonstrated the highest rate of healing ($p < 0.001$).
Conclusions: Patients with intracapsular fractures tend to be younger but have more complications. When comparing methods of fixation, the use of intramedullary nail constructs led to significantly lower rates of nonunion in intracapsular fractures. Better understanding of these fracture populations is important in choosing the best fracture fixation method and in counseling patients on the likelihood of healing complications requiring reoperation.

Table 1

Table 1.

	Extracapsular		Intracapsular	
	Prospective	*Retrospective*	*Prospective*	*Retrospective*
Number of studies	**70**	**89**	**26**	**35**
Patient Pool	10,134	12,832	4,318	2,918
Fracture Pool	10,151	12,907	4,333	2,919
Patients with follow-up *(% drop-out)*	8,022 *(20.8)*	10,819 *(15.7)*	3,753 *(13.1)*	2,659 *(8.9)*
Fractures with follow-up	8,028	10,894	3,760	2,660
Total studies	159		61	
Total patients*	18,841		6,412	
Total fractures*	18,922		6,420	
Mean age (range)	75.3 years (18-105)		67.8 years (18-106)	
Mean follow-up	1.46 years		2.98 years	

Table 1. Patients with extracapsular fractures were significantly older than those with intracapsular fractures ($p < .00001$) and had a much higher drop-out rate due to death and loss to follow-up ($p < 0.0001$). Amongst those that met minimum follow-up requirements, patients with extracapsular fractures had much shorter mean follow-up than those with intracapsular fractures. *Indicates patients and fractures with follow-up.

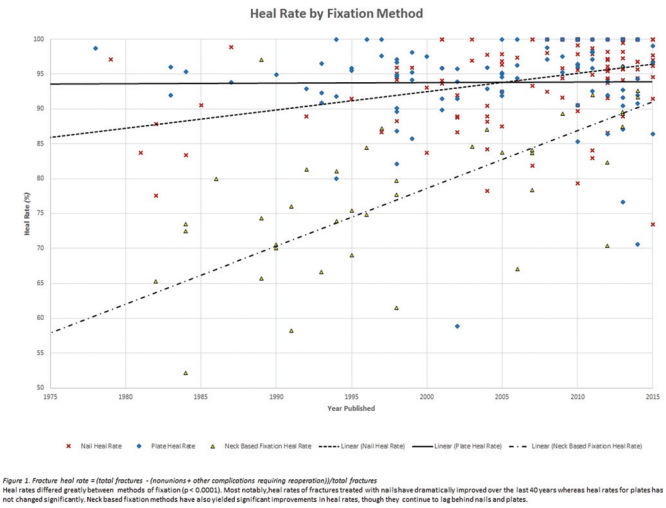

Figure 1:

OS2-15
Lateral cortical notching in specific cases of delayed unions or nonunions after intertrochanteric and reversed fractures

R. Biber[1], H.J. Bail[1], H.-W. Stedtfeld[1]. [1]*Trauma and Orthopaedic Surgery, Paracelsus Medical University, Nürnberg, Germany*

Objectives: Stabilization of both intertrochanteric and reversed trochanteric fractures is commonly performed by proximal femoral nailing. However biomechanics significantly differ between these two fracture types.
Patients and Methods: In this study we report on the occurrence of delayed union or nonunion after inter- or reversed trochanteric fractures in eight patients (seven females and one male).
Results: Mean age was 73.3 years (range: 63–82). The interval between initial operation and first intervention ranged between 4.3 months and 15.0 months (mean: 8.4 months). Failure of bone healing may cause permanent strain on the implant leading to nail breakage, which we observed in three of these eight cases.
Conclusion: Dynamization is part of the general treatment concept for delayed union and nonunion after intramedullary fracture fixation. Normally it is performed by removal of interlocking screws or by occupying a "dynamic" interlocking hole. We can show however that some types of inter- and reversed trochanteric fractures developed a characteristic kind of nonunion at the level of the lesser trochanter. This condition causes pain while walking and includes the risk of implant failure due to material fatigue. In these cases dynamization may be blocked by the cortex of the distal fragment directly contacting the prominent lag screw or its sleeve. We describe a procedure we call "lateral notching", which is needed in order to make distal conventional dynamization effective and to allow for bone healing.

OS2-16
Risk factors for cut-out of double lag screw fixation in proximal femoral fractures

K. Buyukdogan[1], O. Caglar[1], S. Isık[1], C. Aksoy[1], M. Tokgozoglu[1], B. Atilla[1]. [1]*Hacettepe University, Ankara, Turkey*

Objective: We assessed factors associated with cut-out after internal fixation of proximal femoral fractures using double lag screw nails.
Patients and Methods: Patients with intertrochanteric femur fractures who underwent internal fixation with dual lag screw nails were included. We assessed potential risk factors such as age, gender, body mass index, comorbidities (American Society of Anesthesiologists [ASA] classification), type of fracture (AO/OTA classification), fracture stability, side, operation time, implant length, reduction quality, tip-apex distance (TAD), and lag screw configuration. Logistic regression was used to investigate potential predictors of screw cut-out.
Results: In total, 118 hip-fracture cases were treated in the study period; 85 of the 118 fractures reviewed (27 men, 58 women), with a mean age of 77.4 years (range: 50–95 years) met the inclusion criteria. Cut-out was observed in nine (10.5%) patients. No statistically significant differences was found in gender ($p = 0.923$), body mass index (BMI) ($p = 0.253$), operation time ($p = 0.202$), type of lag screw configuration ($p = 0.723$), fracture stability ($p = 0.727$), or AO fracture classification ($p = 0.479$) between the two groups. In univariate analyses, significant variables were age ($p = 0.155$), right side ($p = 0.170$), reduction accuracy ($p = 0.071$), implant length ($p = 0.068$), TAD ($p < 0.001$), and higher ASA score (of 3–5; $p = 0.124$). In a multivariate analysis, statistically significant differences were found for TAD ($p = 0.003$) and moderate reduction quality ($p = 0.045$).
Conclusions: Our study confirmed that risk factors for cut-out with single-lag screw devices are also applicable to dual-lag screw implants. We found that reduction accuracy and TAD were significant factors for cut-out in dual-lag screw implants. Thus, screw cut-out can be minimized by optimizing fracture reduction and screw position.

OS2-17
LISS plate versus intramedullary nail for femur shaft fractures with polytrauma

K. Durak[1], G. Eken[1], A. Durak[1]. [1]*Emergency, Uludag University, Bursa, Turkey*

Background: Femur shaft fractures are one of the most common fractures seen in emergency department. High energy trauma is required for breaking this strongest bone in human body mostly results polytrauma. Various treatment modalities are available for these challenging fractures. Plating and nailing are most popular two options for minimal invasive osteosynthesis. Aim of this study is to compare the outcomes of intramedullary nail versus plate for femur shaft fractures.
Methods: From January 2013 to March 2015, 87 patients with 92 femur shaft fractures with polytrauma were evaluated. Closed reduction and internal fixation acquired with antegrade intramedulary nailing (IMN) to 44 fractures (Group A), less invasive stabilization system (LISS) plate to 48 fractures (Group B). The average age was 45.2 (62–18). Mean follow up time was 30.2 (12–39) months. 45 (48.9%) pulmonary, 32 (34.7%) cranial, 25 (27.1%) abdominal trauma were recorded. Radiographic and clinical follow-up records (bone union rate and time, complications, knee and hip flexion) were retrospectively analysed.
Results: Clinical and radiographic evaluation demonstrated osseous healing within 5 months following IMN and LISS plating were 97.7% and 95.8%. Superficial infections (1 patient Group A, 3 patients Group B), deep infection (1 patient Group B), deep vein thrombosis (1 patient Group A) was detected. However, no statistically significant differences were found for healing time, nonunion rate, and postoperative complication parameters. For all fractures hip and knee flexion were more than 90 degrees at their last control.
Conclusion: For femoral shaft fractures, antegrad IMN and LISS plate can obtain satisfactory clinical outcomes with high union rates, minimal complications, and good recovery of limbs function as being strictly faithful to biological fixation principles. Both method leave little footprints to soft tissue envelope and femur during internal fixation.

Session III: Nail vs. plate vs. prosthesis: humerus

OS3-18
Treatment of proximal humeral fractures in Germany: a representative survey

T. Harnoß[1], M. Weigl[2], U. Schreiber[3], G. Täger[1], A. Lenich[4]. [1]*Trauma Surgery, Klinikum Kempten, Kempten (Allgäu), Germany,* [2]*Technical University , Munich, Germany,* [3]*University of Applied Science, Munich, Germany,* [4]*Department of Orthopedics and Traumatology, Helios Clinic, Munich, Germany*

Question: Despite numerous studies the optimal treatment of proximal humerus fractures remains lively debated. The present survey was to clarify the current treatment situation in German hospitals with focus on diagnosis, treatment and care concepts.
Methods: In this study, all German hospitals with trauma/orthopedic departments (n = 1023) were included. The internal standards required for pre- and post-operative diagnosis, the implant systems used depending on the fracture type and the current treatment concepts for the postoperative treatment were of interest.
Results: 251 questionnaires were used for statistical analysis. In average 52 cases are treated surgically and 34 cases conservatively per year in every hospital. Only 9% of all participating hospitals treat more than 100 patients per year surgically. Angular stable plates are the most widely used implants. Simple fractures tend to be treated with an intramedullary nail, complex fractures with angule stable plates and severe fractures involving the articular surface are treated by endoprosthesis. A primary prosthetic treatment is rarely used, whereas 50 hospitals (20%) use prosthetic treatment in more than 10 patients in a fracture situation each year. A CT scan is part of the primary radiologic examination in 82% of the hospitals. 58 hospitals (23%) do this by default for displaced proximal humeral fractures. A gain of information by CT examination is reported by 90% of the interviewed. For the post-operative treatment major differences were reported, ranging from consistent immobilization up to early functional exercising.
Conclusions: The treatment of proximal humerus fracture remain a complex issue to which no clear recommendations can be made. A proven and standard applied fracture classification is still lacking and clear treatment plans depending on the fracture classification are missing. Even diagnostic algorithms are lack in an evidence-based algorithm. Regarding the treatment options, trends reveal, but clear guidelines are still lacking. The post-operative treatment is very heterogeneous. Again, the evidence-based treatment algorithms are lacking. A limitation of this work is the low response rate of 24% of the questionnaires.

OS3-19
Proximal humeral fractures: mechanisms of failure and trouble-shooting

R. Haase[1]. [1]*Trauma Care and Orthopedics, Bethel Hospital Berlin, Berlin, Germany*

Regarding treatment of proximal humeral fractures various factors e.g. bone-quality, blood supply, articular surfaces and concomitant lesions of the ligaments, tendons and nerves should be taken to account. In recent years the options for an operative treatment have vastly expanded from K-wires and T-plates to numerous angular stable intra- and extramedullary implants and joint-replacement systems.
Before treatment of these fractures many important decisions have to be made: Conservative vs. operative treatment, timing of surgery, choice of procedure and implant as well as surgical approaches.
In some of these cases our judgment and our pre- and intraoperative decisions prove wrong. This may lead to difficult situations in the O.R. and in revision-surgery.
The aim of this lecture is to highlight decision-strategies to avoid numerous pitfalls. A route of standard diagnostic procedures and possibilities is presented. Ten typical cases, where at some point poor decisions have been made and the found solutions and outcomes are presented.
The main issues we learned from these cases are: Get a CT-scan (if possible with 3D-reconstruction) before surgery and also in many cases where we opt for a conservative treatment. In some cases an additional MRI may be helpful. If we are not sure that our chosen procedure really works in the O.R. we should get sufficient backup solutions (alternative implants, joint replacement etc.) before surgery and we should talk about them with our patients. The chosen surgical approach should be an option also for our backup-solution. Permanent resection of the humeral head is not an option. Soft tissue lesions should be treated appropriately. Sound exercise stability is mandatory in the treatment of proximal humeral fractures.

OS3-20
Is it safe to assist proximal humeral nailing to residents? An analysis of 1134 cases

R. Biber[1], B. Altintas[1], H.J. Bail[1]. [1]*Trauma and Orthopaedic Surgery, Paracelsus Medical University, Nürnberg, Germany*

Introduction: Intramedullary nailing is a common procedure for the treatment of proximal humeral fractures. In practical resident training this standardized operation plays an important role in the introduction to osteosynthesis. Our aim was to investigate whether assisting this operation to residents influences the surgical complication rate both in-house and on re-admission.
Methods: All 1134 patients who received a proximal humeral Targon PH nail (Aesculap) for proximal humeral fractures were included between 2000 and 2013. Complications including screw/nail protrusion, displacement, infection, humeral head necrosis, non-union, stiffness, hematoma, impingement, screw loosening. implant failure, dislocation were recorded.
803 (70.7%) of the patients were female. Mean patient age was 71.7 years. For detection of significantly different complication frequencies between operations performed by residents or attending physicians, we used the c^2 test or two-sided Fisher's exact test (as applicable).
Results: Supervised residents performed 204 operations. Overall complication rate was 12.6% (95% CI: 10.7–14.5%). The complication rate of the attending operations was 13.2% while it was 9.8% for resident operations. The difference was not significant. No statistically significant relation between age group and complication rate was found.
In patients older than 80 years the complication rate was higher when operated by residents compared to consultants, whereas in younger patients it was lower. We found significantly less complications in the group of patients between 61 and 80 years of age. On the other hand patients between 81 and 90 years displayed a 1.46 fold higher risk after training operations.
No significant differences in the frequency of the different complications were found.
Conclusion: We conclude that proximal humeral nailing is an operation suitable for teaching purposes. However patients between 81 and 90 years of age seem to be at an increased risk for complications if operated by a resident.

OS3-21
Experimental examination of factors influencing the deformation cut out risk in locked nail osteosynthesis of proximal humerus fractures

S. Fleckenstein[1], W. Friedl[1], M. Rinner[2]. [1]*Klinikum Aschaffenburg, Chirurgische Klinik 2, Aschaffenburg, Germany;* [2]*Plus Orthopedics, Aarau, Switzerland*

Introduction: Locked nail osteosynthesis allows a minimal invasive stabilization of the very frequent proximal humerus fractures. However most patients are elderly with poor bone quality and the proximal humerus is biomechanically highly loaded. The factors influencing the cut out risk were examined in an alternating load test model.

Figure 1:

Material and Methods: As standard model a PHN series with spiral blade and screw fixation was used. As test implant a device with the option of 4 locked screw fixations and an additional possibility of a fork blade over the central screw was tested under different locking alternatives. HGN = humerus gliding nail. A subcapital defect osteotomy for deformation testing (1,000 cycles between 50 and 150 N) and an osteotomy along the anatomical column for cut out were tested with 1,000 cycles between 50 and 300 N load. In each group 5 sawbones were tested.
Results: The deformation in all groups increased from the first to the 1,000th cycle. The mean deformation was 1 mm for the HGN blade, 1,1 mm for the HGN screw and 1,55 mm for the PFN group. The results differed not significantly. In the cut out test the rate of cut out was similar for the PHN and the HGN with a single screw. Whereas the cut out rate for the HGN with 4 screws was reduced by 50% and the use of the blade in addition to the central screw reduced the cut out risk by 66%. However the standard deviation was very high.
Conclusions: For a reduced deformation and cut out risk the most important factor is the number of locking elements. The combination of locked screws with a fork blade resulting in a higher implant to bone contact-surface improves the cut out rate but in the small series the differences are not significant.

Figure 2:

OS3-22
Complication analysis of the Targon® PH nail

H.J. Bail[1], B. Altintas[1], B. Zirngibl[1], M. Curschmann-Horter[1], R. Biber[1]. [1]*Trauma and Orthopaedic Surgery, Paracelsus Medical University, Nürnberg, Germany*

Introduction: Antegrade nailing is a widespread technique for the treatment of humeral head and shaft fractures. The Targon® PH nail is one of the most prevalent implants, which is available in standard and long versions. Yet reports on large case series are missing.
Patients and Methods: Prospective documentation of all Targon® PH cases since its introduction in 2000. Beside demographic data and fracture classification we analyzed surgical complications causing re-admission or re-operation. We also evaluated the rope-over-bitt technique (ROB), which is an additional tension banding fixation method for comminuted tuberosities.
Results: In 1,135 cases (median age: 74 years; average operation time: 73.5 min for standard nails and 95.8 min for long nails) we found a surgical complication rate of 12.6%, which was higher for standard nails than for long nails (14.3% vs. 9.0%; $p = 0.028$). Analyzing Neer IV fracture cases, operative time in ROB cases was significantly higher (88.2 min vs. 73.8 min; $p < 0.001$). However there was no significance for a higher surgical complication rate after ROB (20.2% vs. 16.4%; $p = 0.46$).
Conclusions: Our study confirms low surgical complication rates. Indications for the long Targon® PH nail include proximal third shaft fractures, segmental fractures, and pathologic fractures. ROB is a safe way to enhance fixation of comminuted tuberosities.

OS3-23
Humeral head necrosis after proximal humeral nailing: what are the reasons for bad outcome?

H.J. Bail[1], B. Zirngibl[1], R. Biber[1]. [1]*Trauma and Orthopaedic Surgery, Paracelsus Medical University, Nürnberg, Germany*

Introduction: Humeral head necrosis (HHN) remains a major problem in fracture care. This study was designed to evaluate clinical and radiological outcomes in patients depending on the influence of HHN.
Patients and Methods: 310 patients operated between 2006 and 2010 were operated with a standard Targon PH nail for an acute humeral head fracture. 32 (10.3%) patients could be obtained for follow-up including Constant score (CS), DASH score, UCLA shoulder rating scale, and Neer score. ROM as well as pain was documented. The follow-up period was 3 to 6 years after injury. HHN was detected radiologically and graded in stages 0–5.
Results: All fractures had healed. HHN was found in 10 cases (31.3%). 4 patients (12.5%) showed interlocking screw perforation as part of the head collapse caused by HHN.
Median CS was 73 (range: 24–85). There was no association detectable between number of fracture fragments and CS ($p \geq 0.631$). The median DASH score was 16.4 (range: 0–74.1), UCLA score 30 (range: 9–35), Neer score 80 (range: 29–100).
Three (37.5%) of the patients with a stage IV or V osteonecrosis reported about pain. All patients with pain were affected by high grade HHN and screw perforation. CS was not affected by HHN, however significantly diminished if additional implant protrusion was present. Findings for normalised CS, relative CS, DASH score, UCLA shoulder rating scale, Neer score, and ROM were analogous.
Discussion: Whereas HHN itself seems to contribute only mildly to functional outcome, we identified screw protrusion as major predictor for bad clinical results. The high rate of HHN found in our study (31.3%) may be attributed to the inclusion of mild HHN and our long follow-up period, as it is known that late-onset HHN may occur more than 3 years after trauma.

OS3-24
Intramedullary nail vs dynamic compression plate in treating humeral shaft fractures

C. Bardas[1], H. Benea[1], D. Oltean[1], M. Paiusan[1], R. Tomoaia[1], A. Bardas[1], G. Tomoaia[1]. [1]*Orthopedics and Traumatology, UMF "Iuliu Hatieganu", Cluj-Napoca, Romania*

Objectives: The purpose of this study is to compare the results obtained using an intramedullary nail versus a dynamic compression plate in the treatment of humeral diaphysial fractures.
Materials and Methods: The study was conducted retrospectively on a total of 103 patients (46 males, 57 females) admitted in the Orthopedics and Traumatology Clinic, Cluj-Napoca, Romania between January 2014 to January 2016. We have included in the study patients diagnosed with AO 12-A, 12-B humeral shaft fractures. Complex fractures, pathological fractures, open fractures were excluded from the study. 35 patients were treated using an antegrade intramedullary nail (14 patients benefited from closed reduction, internal fixation); 68 patients were treated using a dynamic compression plate (lateral approach). All patients followed the same rehabilitation protocol. The evaluation of the patients was performed considering the radiological outcome, complications and functional outcome (range of motion of the shoulder and elbow, any pain or disability).
Results: The consolidation of the fracture was similar in both groups, although the patients treated with IN presented a shorter healing time (6.3%). The functional outcome was the same in both groups. The rate of complications encountered was about 5.7% in the IN group (1 infection, 1 nonunion) and about 10.2% in the DCP group (1 infections, 1 nonunion, 3 hardware failures, 1 radial nerve palsy).
Conclusions: Using an intramedullary nail or a dynamic compression plate in treating humeral shaft fractures showed similar results in terms of consolidation and functional outcome. Fewer complications were encountered in the IN group.

OS3-25
Minimally invasive plate osteosynthesis by anterior approach: an alternative in distal humeral shaft fractures produced by arm wrestling

P-D. Sirbu[1], G. Berea[1], R. Asaftei[1], R. Tudor[1], R. Sova[1], A. Bodescu[1]. [1]*Orthopaedics, Gr.T. Popa Medicine and Pharmacy University, Iasi, Iasi, Romania*

Purpose: The purpose of this prospective study is to demonstrate the safety, efficiency and feasibility of minimally invasive plate osteosynthesis (MIPO) by anterior approach in distal humeral shaft fractures, produced by arm wrestling.
Methods: We have operated 10 distal humeral shaft fractures using indirect reduction and biological plating. Following limited proximal and distal incisions, a molded plate was inserted from distal to proximal and fixed on to the shaft with a least 2 proximal and 2 distal screws. All patients were followed for at least 24 months. The operating time, radiation exposure, postoperative complications, time to fracture healing, the Constant score for shoulder and Mayo elbow performance index (MEPI) were recorded.
Results: The mean operating time was of 66.5 minutes (range 45–100 minutes) with a mean radiation exposure of 19.7 seconds. All fractures healed with a mean time of 9.6 weeks following surgery. There were no vascular or nerve complication except one transient postoperative paresthesia for the radial nerve. The functional results were excellent according to Constant score for shoulder (average 100 points) and MEPI score for elbow (average 100 points).
Conclusions: For the distal third humeral shaft fractures produced by arm wrestling, we consider that MIPO by anterior approach represent the optimal approach, regarding safety and feasibility, faster rate of union and better functional results compared to conservative techniques. Even demanding, MIPO does not require special instruments, expensive implants or excessive radiographic controls.

OS3-26
New multidirectional angular stable plate fixation in transcondylar humerus fractures: Trochlius plate

A. Terzis[1], W. Friedl[1]. [1]*Klinikum Aschaffenburg, Aschaffenburg, Germany*

Introduction: The fixation of the trochlea is very difficult if there is a fracture line between the trochlea and the medial column and the medial epicondylus. All actual plates reach only the distal level of the medial epicondylus so fracture dislocation can occur. A direct transverse angle stable fixation of the trochlea and also of the entire articular block in multifragment fractures can be performed only with a different plate design with a 90 degree angulation between the articular block and the medial column fixation.
Question: We developed a plate which allows a direct transversal multidirectional screw fixation of the trochlea and the articular block and proximally the simple anteroposterior fixation of the medial column. It can be also used for isolated fractures of epicondylus fragments. For the radial column a standard anatomical plate is used.
Methods: In a pilot study the Trochlius plate was used in 10 patients. We used plates for right and left side, small and large length depending on the metaphyseal extension of the fracture. There were used 4 types of plates for the right and 4 for the left side. In all cases after open transulnar reduction of the fracture and temporary K-wire retention the plates fitted anatomically and allowed fixation even in very complex transcondylar impacted fractures. The ventral trochlea and capitulum humeri can be as well fixated with angular stability. The ulnar nerve is repositioned over the plate because the screw heads lie on the plate surface.
Results: In this pilot study there was no case of redislocation, instability or infection. In a single open fracture a haematoma revision was necessary but healing was not affected. All fractures showed a stable healing within 6–9 weeks.
Conclusions: The new design of the Trochlius plate allows for a stable fixation of very difficult transcondylar fractures, especially trochlea fractures. Thus the elbow joint arthroplasty can be avoided in these often considered as unreconstructable fractures.

Session IV: Nail vs. plate vs. prosthesis: wrist and forearm

OS4-27
Classification, treatment and clinical results of the Monteggia like lesion in 28 patients

L. Eden[1], D. Ziegler[1], H. Jansen[1], R.H. Meffert[1]. [1]*Traumatology, University Clinic Würzburg, Würzburg, Germany*

Question: Monteggia fractures account for 2–5% of all forearm fractures and are thereby seldom injuries including a proximal ulna fracture and dislocation of the radial head. They are often associated with high complication rates and a mean clinical outcome. Clinical trials are rare so that precise recommendations for the treatment and outcome parameters are limited. We analysed all Monteggia fractures treated in our clinic since 2009 and performed a clinical survey retrospectively with a minimum follow-up of 1 year.
Methods: 28 patients fulfilled the requested criteria of the survey. 22 of those accounted for Bado type 2 fractures, the rest were type 1 lesions. All patients were treated operatively with a plate-fixation of the ulna. We used regular or precontured LCP (Depuy-Synthes) or twin plates (Medartis) for the ulna. In case of radial head fracture we performed a fixation through the ulna-fracture with an anconeus flap in a one approach manner. 5 patients were not eligible because 3

passed away, 1 moved away and 1 arm amputation. We recorded the range of motion, visual analogue scale for pain and function, DASH and Mayo-Elbow-Score. The average follow up was 46 months.
Results: The average range of motion for flexion reached 128° and extension 16°, accounting for a flexion amplitude of 112°. The total forearm turning including supination and pronation was 132°. The VAS for pain was 22 of 100, function reached 73 of 100. The average Mayo-Score was 81, the DASH-Score 30 points.
Complications (28.6%) occurred in terms of 2 non-unions of the radial head without revision, one screw malposition at the ulna with revision, one resection arthroplasty of the radius and 3 early implant removals because of disturbing implants at the ulna. One CRPS was diagnosed. Recurrent instability or infection was no problem seen in our survey.
Conclusion: The Monteggia lesion is a demanding injury that mainly leads to a relatively high complication rate and functional deficit. Our survey also revealed a decent amount of complications and persisting functional deficit. But we proofed on the other hand that our way of treating this injury with modern implants successfully faced the basic problems of instability and fracture healing at the ulna. The average range of motion is good enough to withstand the demands of everyday life. Nevertheless a restitutio ad integrum is still not reached in the majority of cases, so that further improvements are required in the future.

OS4-28
Locking plates or locking internal nail in distal radius fractures: an experimental examination and phase I clinical study

L. Höchtl-Lee[1], W. Friedl[1]. [1]*Orthopedic and Trauma Surgery, Klinikum Aschaffenburg-Alzenau, Aschaffenburg, Germany*

Background and Aim: Distal radius fractures frequently affect elderly women with substantial comorbidities, such as osteoporosis, resulting in diminished bone density, making treatment more demanding. Dorsal and volar comminution is frequent and requires reduction and a stable osteosythesis by a locking implant. For this, the most common stabilization device is the volar, multidirectional locking plate, although intramedullary devices such as Micronail or Targon DR have been introduced. These implants require placement through the demanding insertion of awls, elevating the risk for further bone injury. The XS nail was therefore tested to provide an easy, locking and stable implant requiring only a guide wire and subsequent drilling in either 3,5 mm or 4,5 mm. Through its fixation with threaded wires, it allows for a stable, multidirectional fixation of extra articular fractures of the distal radius.
Methods: 16 radius sawbones were osteotomised corresponding to A3 type fractures and stabilized with either a locking plate (8) or XS nail (8). Deformation was registered throughout 1000 cycles of alternating loads of 20–200 N, and a FE analysis was subsequently performed using MSC Patran/Marc software. Based on the results, an anatomically adapted XS nail, the XSR, was developed and used in 100 patients matching the indication criteria. (Fracture type AO A3, C1 and C2)
Results: While both devices showed good biomedical and physical results as well as solid osteosynthesis and good stability, the XSR group showed a 20% lower deformation of 0,31 mm (+/–0,04 mm) compared to the plate (0,42 mm, +/–0,08 mm). The calculated FE was also lower by 20% in the nail group, but not statistically significant, due to the small number. The patient follow up of 100 patients showed only one partial loss of reduction and the breakage of two threaded wires.
Conclusion: The simple insertion with guided wires from the styloid process of the radius after exposure of the superficial radial nerve, intramedullary position and angular stability of its wires are the main advantages of the XSR. Moreover, initial clinical results show promising outcomes without the need of exposing the pronator quadratus muscle or median nerve.

OS4-29
Outcome of conservative versus volar locking plate osteosynthesis for unstable distal radius fractures: a comparative study

A.M. Teja[1], R.C. Banshiwal[1]. [1]*Orthopaedics, Sawai Man Singh Medical College and Hospital, Jaipur, India*

Materials and Methods: This was a prospective comparative study which included 50 cases of distal radius fractures. Conservative group 32 cases and operative group 18 cases.
In operative group 78% cases had Fernandez type 2 and 3 fractures which indicate comminuted intra articular fractures (78% males and 22% females).
In conservative group 84% cases had Fernandez type 1 and 2 unstable fractures (53% males and 47% females).
Radiographic and functional outcomes were assessed at 3 months and 6 months.
Results: Radiographic results in operative group – 100% had well to excellent results while in conservative group 30% had excellent results, 17% had good results and 53% had fair results.
At 3 months functional results in operative group – 95% had good to excellent results while 5% had fair results while in conservative group 28% had good results 62% had fair results and 9% had poor results.
At 6 months in both groups functional results were improved. In operative group 100% had excellent results while in conservative group 48% had excellent, 44.44% had good, and 7% had poor results respectively.
Conclusion: This evidence indicates that volar locking plates may be advantageous for a patient who desires an accelerated return of functions.
Conservative group results suggest that timing and number of follow up visits need to individualized to both the patient and the fracture. Good anatomical restoration with intense physiotherapy is key to success. We believe that the subjective short term advantage of the use of a volar plate is robust and applicable to the treatment of unstable distal radius fractures.
This study provides new evidence supporting the trend towards fixation of distal radius fractures with volar locking plates.

OS4-30
Treatment of multi fragmentation fractures of the distal extremity of the radius with dorsal displacement (C type)

B. Gogulescu[1]. [1]*Orthopedic and Trauma, Clinical Emergency Hospital "Sf.Ap.Andrei" - Galati, Galati, Romania*

Introduction: Fractures of the distal radius occur in approximately 18% of patients admitted within the Emergency Department. Their incidence is highest after the age of 50. They occur in people with balance disorders, while reducing resistance and bone density by reductions in physical activity and decreased muscle tone. The first descriptions appear after 1800, but the treatment of these injuries is not even today standardized. It is believed that restoring the anatomical shape of the distal radius is the condition of a good functional outcome and of living standard conservation.
Purpose: Studied maintaining the stability of fractures of the distal radius with dorsal displacement (C type), reduced by external maneuvers and external fixation.
Methods: During 2013–2015, from a total of 1869 injuries with distal radius fracture, were hospitalized and operated 158 cases. 39 patients from these cases were treated by distraction and external fixation.
Radius fixation and in metacarpal II monoplanar or multiplanar fixators used.
Osteosynthesis was practiced in 20 emergency cases or after failure of conservative treatment was found for 19 cases.

Distraction level, duration of external fixation and functional recovery were adjusted depending on the degree of instability, the degree of cooperation, bone density and tolerance of the fixator's sheets.
Monitoring and assessment of the results was done on an average of 8 months.

Figure 1:

Results: Results were assessed using the DASH system.
Grades obtained were excellent in 38.4% (15 cases), good in 43.6% (17 cases), satisfactory in 15.4% (6 cases) and unsatisfactory in 2.6% (1 case).
Results are obtained on most unstable cases (type C fractures).

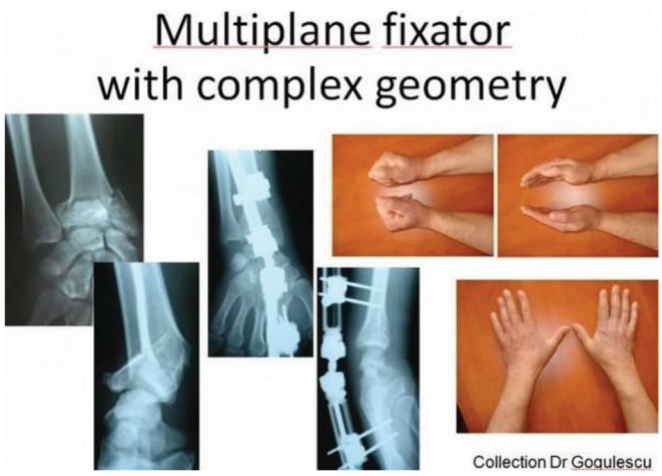

Figure 2:

Conclusion: Ligamentotaxis is used with maximum efficiency in emergency cases. Restoring the anatomy of the distal radius and limiting the digital stiffness is possible if you apply external fixator in emergency.
Using external fixator in failure of the conservative treatment requires a higher pressure and the interfragmentary distraction is also transmitted to the articulation of the wrist.
Tolerances in external fixator depend on individual characteristics.
A single dose of antibiotics was administrated before surgery, according to the general scheme for ensuring safety in emergency situations.
Joint stiffness, chronic inflammatory syndrome subside in the first months of rehabilitation treatment.

OS4-31
The Amsterdam wrist rules, an implementation study

M. Mulders[1], M. Walenkamp[2], J.C. Goslings[1], N. Schep[2]. [1]*Academic Medical Center, Surgery, Amsterdam, Netherlands,* [2]*Surgery, Maasstad Hospital, Rotterdam, Netherlands*

Question: Today, patients with wrist trauma are routinely referred for radiography of the wrist. However, around 50% of these radiographs do not show a fracture. Currently no guidelines exist to endorse decision-making regarding this referral. This may result in unnecessary X-rays and therefore in unnecessary radiation exposure to patients and increased waiting times at the Emergency Department (ED). Encouraged by the lack of clinical guidelines regarding the X-ray referral policy for patients with wrist trauma, we developed and validated a clinical decision rule in adults: The Amsterdam Wrist Rules (AWR). This clinical decision rule helps to determine the need for an X-ray in patients with wrist trauma. The AWR has been validated and has shown a sensitivity and specificity for detecting fractures of the distal radius in adults of respectively 98.4% and 25.1%. The aim of the current study is to evaluate the implementation of the Amsterdam Wrist Rules at the Emergency Department (ED).
Methods: This implementation study was designed as a "before and after" diagnostic prospective cohort study with a historical reference group. All consecutive adult patients presenting with acute wrist trauma at the Emergency Department (ED) of one University and three teaching hospitals were included. Primary outcome was the reduction of radiographs requested at the ED after implementation of the AWR. Secondary outcomes were the number of clinically relevant missed fractures, physician acceptability and compliance regarding the AWR and patient satisfaction and experience with the received care at the ED.
Results: From November 2014 till January 2016 a total of 399 patients were included. The median age was 50 years and 61% of patients were female. The absolute reduction in radiographs requested was 15.5%. Due to the recommendation of the AWR one fracture was missed, however this fracture was not clinically relevant. In 4% the physicians adhered to the AWR. The main reason not to adhere to the recommendation of the AWR, was a suspected fracture of the scaphoid. Except for three patients, all patients felt secure with the fact they did not receive a radiograph of the wrist.
Conclusions: Implementation of the AWR at the ED results in an absolute reduction in requested radiographs of the wrist of 15.5%, without missing any clinically relevant fractures. However, only 4% of physicians adhered to the recommendation of the AWR.

OS4-32
Long-term functional outcomes after corrective osteotomy of distal radius malunions

M. Mulders[1], P. d'Ailly[1], B. Cleffken[2], N. Schep[2]. [1]*Surgery, Academic Medical Center, Amsterdam, Netherlands,* [2]*Surgery, Maasstad Hospital, Rotterdam, Netherlands*

Question: Malunion is the most common complication after fractures of the distal radius. The decision whether to surgically treat distal radial malunions is based primarily on functional demand and pain of the wrist. The purpose of this study was to evaluate the long-term functional outcomes of corrective osteotomy after malunion of the distal radius.
Methods: All corrective osteotomies of the distal radius from a single hospital between 2009 and 2015 were included in this study. Demographic data and surgical details were retrieved from the hospital's medical file. Additionally, all patients were invited to the outpatient clinic for a follow-up visit. The primary outcome was the functional outcome assessed with the DASH and PRWE score. Secondary outcomes were range of motion and grip strength (compared to the uninjured wrist), pain as indicated on the Visual Analogue Scale (VAS) before and after corrective osteotomy,

radiological parameters, time to union and complications requiring additional treatment. Paired Students t-Test was used to compare radiographic parameters from before and after corrective osteotomy. Independent Student's t-Test was used to compare range of motion and grip strength of the injured and uninjured side and to compare VAS pain scores from before and after corrective osteotomy.

Results: A total of 52 patients were included in this study. The mean age was 53.3 years (SD 15.4) and 71% was female. The mean time to follow up was 39 months (range five to 169 months). Forty-six patients underwent a distal radius open wedge osteotomy and shortening of the ulna was performed in six patients. Out of the 44 patients that completed the DASH questionnaire, the median score was 10.0 (IQR 5.6 to 18.9). Out of the 43 patients that completed the PRWE questionnaire, the median score was 13.5 (IQR 4.5 to 27.0). All radiographic parameters improved significantly compared to the pre-operative status ($p < 0.01$). The median time to union was 24 weeks (range four to 128). Dorsal and palmar flexion of the wrist and ulnar deviation showed a significant difference compared to the uninjured wrist. VAS scores decreased significantly from 5.8 preoperative to 1.5 postoperative ($p < 0.01$). Complications occurred in 54% of the patients. Re-corrective osteotomies had to be performed in 7 patients, two due to non-union and ulnar abutment and 5 due to hardware failure.

Conclusions: Corrective osteotomy is an effective method of treating distal radius malunion with good long-term functional results. Both DASH- and PRWE-scores were low and pain scores decreased after the corrective osteotomy. Moreover, radiographic parameters improved significantly after the corrective osteotomy.

Session V: Nail vs. plate vs. prosthesis: distal lower leg, pilon and ankle fractures

OS5-33

Surgical treatment of distal tibia fractures with intra-medullary nail

D. Vermesan[1], C. Faur[1], B. Anglitoiu[1], M. Oprea[1], D.V. Poenaru[1]. [1]*2nd Clinic of Orthopaedics and Traumatology, "Victor Babes" University of Medicine and Pharmacy, Timisoara, Romania*

Introduction: Fractures of the distal tibia in the adult result from a combination of axial compression and rotational forces.

Surgical treatment of extra-articular fractures of distal tibia is a controversial topic throughout the entire literature. The recent development of more distal locking options with IM nails and anatomically-contoured angle-stable plates have improved our ability to stabilise these fractures.

Material and Methods: This study included 27 patients admitted and treated for distal extra-articular tibial fractures (AO 43 A1-3) between Jan 2012 and May 2015 in the 2nd Clinic of Orthopaedics and Traumatology. Ten patients sustained open fractures (two type I GA, four type II GA and four type IIIA GA). Nine patients also had distal peroneal or peroneal malleolus associated fractures and 18 had associated supra-malleolar fractures of the peroneus.

IM nailing was the treatment choice for all cases (with reaming in 14 cases) and for the associated peroneal fractures ORIF with plates and screws was performed.

Results: From a total of 27 cases, 4 (14.8%) cases healed with a varum >5° deformity, 3 (11.1%) cases developed pseudarthrosis that necessitated further surgical treatment (angular stable plates and bone graft), 1 (3.7%) case had intraarticular nail migration and infection, 19 (70.4%) cases had a favourable evolution with good outcome.

All fracture healing complications appeared within the cases treated without medullary canal reaming and without associated distal peroneal fractures.

Conclusions: Cases treated with ORIF for distal peroneal fractures had better results that those treated by conservative means. IM nailing can be extremely important in open fractures where it can provide excellent fixation of the fracture fragments and allows, if necessary, extensive debridement and reconstructive treatment for soft tissues without direct implant exposure. It was also noted that reamed nailing was biomechanically superior in terms of stability to the unreamed nails.

OS5-34

Comparison of plate versus intra-medullary nail fixation for distal tibia fractures without articular involvement

M.C. Sozbilen[1], G. Hatami[1], K. Kayaokay[1], O. Suer[1], N. Ozkayin[1], K. Aktuglu[1]. [1]*Orthopedics, Ege University, Izmir, Turkey*

Aim: The objective of this study was to evaluate distal tibia shaft fractures treated with plate or nail in terms of radiographic & clinical results and complication rates.

Methods: 109 patients with distal tibia shaft fractures (3 and 11 cm proximal to the ankle joint) were reviewed retrospectively between July 2008 and December 2015. The fracture pattern, AO classification, open fracture, complications and union were evaluated after a mean of 24 months (12–65 months range). Patients were divided into three groups according to the location of fractures (proximal, middle and distal). Statistical analysis was performed utilizing SPSS v21.

Results: 47 women and 62 men with a mean age of 39.41 years (18 to 71) were evaluated. 43 fractures were treated with an intramedullary nail and 66 fractures were treated with a plate. 58 patients (53.2%), 35 patients (32.1%) and 16 patients (14.7%) were classified according to AO classification as 42-a, 42-b and 42-c, respectively. 23.8% of the patients had open fractures. Osteomyelitis developed in four patients (3.9%): three of the patients after plating and one of the patients after intramedullary nailing. Only one patient from each group had nonunion. However, 15 patients (13.8%) had delayed union, ten patients (9.1%) developed delayed union after nailing versus five (4.5%) plating *(p. Seven of all delayed unions (46.6%) were in proximal part ($p \geq 0.05$). The absence of concomitant fibula fracture is not related to delayed union (p. Angular malalignment of ≥3 degrees occurred in nine patients with nails (8.2%) and 14 patients with plate (12%) ($p \geq 0.05$). Valgus was the common deformity ($n = 12$).*

Conclusions: High union rates were determined after surgical treatment of distal tibia shaft fractures with both plates and intramedullary nails. Delayed unions were more frequent after nailing however malunion was not significantly different between nailing versus plating. Location of fracture does not affect the union or malunion rates.

OS5-35

Biomechanical analysis of three fixation methods in treatment of pilon fractures AO 43-C3

B. Puha[1], T.S. Gheorghevici[1], E. Carata[2], W. Friedl[3], S. Rares[4], P.-D. Sîrbu[1,4]. [1]*Orthopedics, Grigore T. Popa University of Medicine and Pharmacy, Iasi, Romania,* [2]*Department of Machine Tools, "Gheorghe Asachi" Technical University, Iasi, Romania;* [3]*Orthopädie, Unfall- und Handchirurgie, Klinikum Aschaffenburg-Alzenau, Chirurgische Klinik II, Aschaffenburg, Germany;* [4]*Orthopedics and Traumatology Clinic, Emergency Universitary Hospital "Sf. Spiridon", Iasi, Iasi, Romania*

Introduction: The treatment of pilon fractures is still in debate due to high number of complications and the variety of methods of treatment.

Objectives: to investigate the efficacy of three methods of osteosynthesis of AO 43-C3 pilon fractures, by biomechanical testing: medial locked plate (G1), antero-lateral locked plate (G2) and 2 Xs-nail and screws (G3).

Materials and Methods: We used fifteen synthetic tibia (Sawbones® Tibia, Fourth Generation) with articular and metaphyseal segmental osteotomy in three different planes. Each fracture was reduced and plated with precontoured medial, anterolateral distal tibia plate or fixed with 2 Xs-nail in "X" position and screws. The specimen were biomechanical tested for axial and torsional loading at 200 and 400 N, using a LRX Plus machine (Lloyd Instruments Ltd -AMETEK). We used NEXIGEN Data Analysis and IBM SPSS 18.0 software to collect and analyze: axial and torsional stiffness and construction stability.
Results: Construct optimal stiffness to axial compression was obtained in G1 (with 50.13% of the standard values to small forces and 39.58% from standard to high forces). These values are comparable (and better) than G3 group (32.65% and 29.68% at small forces at large forces). In G2 we achieved excellent stability (CV = 3.27%) the application of small forces. Despite achieving good stiffeners construct, its stability suffers from high forces, reaching values below G3, but remains superior to G1 ($p < 0.05$).
Conclusions: This study showed the biomechanical advantage of medial plating for AO 43-C3 pilon fracture patterns. Although we obtained lower values in XS nail group, it can be considered o valued alternative in selected cases. Future research is needed to explore the opportunity of a new implant with better properties.

OS5-36
Complications associated with lateral malleolus plate fixation in ankle fractures

D. Vermesan[1], R. Prejbeanu[1], H. Haragus[1], D. Poenaru[1]. [1]*University of Medicine and Pharmacy "Victor Babes', Timisoara, Romania*

Plating of the lateral malleolus fracture can associate specific surgical site morbidity. We detail our experience with their management.
We retrospectively reviewed 127 ankle fractures that underwent surgical treatment in our orthopedics department over 4 years. The lateral malleoli were internally fixed using either semi tubular steel plates or titanium with locking screws. 28% returned for hardware removal. 8 patients had wound complications (5 deep infections) of the lateral malleolus which required surgical treatment and another 9 were resolved by extended outpatient visits.
Plate fixation of the lateral malleolus fracture is the current standard of care. However this anatomical area has poor soft tissue coverage which can lead to specific hardware related complications. We question whether or not intramedullary implants may prove to be a safer solution for lateral malleolus fracture osteosynthesis.

OS5-37
Interlocking nailing in intraarticular calcaneal fractures: a biomechanical cadaver study of two different interlocking nails vs. an interlocking plate

T. Mittlmeier[1], S. Reinhardt[1], B. Ulmar[2], H. Martin[3], M. Richter[4], M. Pompach[5], S. Döbele[6], H. Zwipp[7], S. Rammelt[7]. [1]*Trauma, Hand and Reconstructive Surgery, Rostock University Medical Center, Rostock, Germany,* [2]*Department of Orthopaedics, Universität Ulm, Ulm, Germany,* [3]*Department of Biomedical Engineering, Rostock University Medical Center, Rostock, Germany,* [4]*Department of Foot and Ankle Surgery, Klinikum Rummelsberg, Schwarzenbruck, Germany,* [5]*Department of Traumatology, Regional Hospital, Pardubice, Czech Republic;* [6]*BG Unfallklinik Tübingen, Tübingen, Germany,* [7]*Universitätsklinikum Carl Gustav Carus, Universitäts Centrum für Orthopädie und Unfallchirurgie, Dresden, Germany*

Background: Open reduction and internal fixation with a plate are deemed to represent the golden standard of treatment for displaced intraarticular calcaneal fractures. Standard plate fixation requires an extended lateral approach with high risk for wound complications. Minimally invasive techniques might avoid wound complications but provide limited construct stability. Therefore, two different types of locking nails were developed to allow for minimally invasive technique with sufficient stability. The aim of this study was to quantify primary stability of minimally invasive calcaneal interlocking nail systems in comparison to a variable angle interlocking plate.
Material and Methods: After quantitative CT analysis for bone density assessment a standardized Sanders type IIB fracture model was created in 21 fresh-frozen cadavers. For osteosynthesis two different interlocking nail systems (C-Nail and Calcanail) as well as a polyaxial interlocking plate (Rimbus) were used. Biomechanical testing consisted of a dynamic load sequence (preload 20 N, 1000 N up to 2500 N stepwise increase of 100 N every 100 cycles, 0.5 mm/s) and a load to failure sequence (max. load 5000 N, 0.5 mm/s). Interfragmentary movement was detected via a 3-D optical measurement system. Boehler's angle was measured after the osteosynthesis and after failure occurred.
Results: No significant difference regarding load to failure, stiffness, Boehler's angle, interfragmentary motion was found between the different fixation systems. A significant difference could be shown in the event of failure within the dynamic testing sequence where 87.5% of the Calcanail implants failed in contrast to 14% of the C-Nail group ($p < 0.01$) and 66% of the Rimbus plate. The highest load to failure load was observed for the C-Nail. Boehler's angle showed physiologic range with all implants before and after the biomechanical tests. Implant characteristics determined relative motion of fracture elements.
Conclusion: Both minimally invasive interlocking nail systems display a high primary stability not inferior to an interlocking plate and appear to represent a viable option for treating displaced intraarticular calcaneal fractures. Our results correlate well with the clinical midterm results of both calcaneal interlocking nails [1,2].

References

[1] Simon P, Goldzak M, Eschler A, Mittlmeier T. Reduction and internal fixation of displaced intra-articular calcaneal fractures with a locking nail: A prospective study of sixty nine cases. *Int Orthop*. 39(10):2061–7, 2015.
[2] Zwipp H, Paša L, Zilka L, Amlang M, Rammelt S, Pompach M. Introduction of a new locking nail for treatment of intraarticular calcaneal fractures. *J Orthop Trauma.* 30(3):e88–92, 2016.

OS5-38
A new minimally-invasive applied locking nail for displaced intraarticular calcaneal fractures: results after 1 year

A. Eschler[1], A. Brakelmann[1], T. Mittlmeier[1], G. Gradl[2]. [1]*Department for Trauma, Hand and Reconstructive Surgery, University of Rostock, Rostock, Germany,* [2]*Department of Trauma, Orthopedic and Reconstructive Surgery, Klinikum München Harlaching, Munich, Germany*

Question: Surgical treatment of displaced intraarticular calcaneal fractures using a lateral approach is complicated by wound complications and infections. This prospective study evaluates if a minimally-invasive applied intramedullary locking nail provides adequate reduction capacities and is able to reduce the high complication rates.
Methods: 21 feet with displaced intraarticular calcaneal fractures and minimally-invasive fracture reduction and fixation using the intramedullary calcaneal locking nail (Calcanail®) were observed clinically and radiologically for one year postoperatively. Follow-up included CT-based radiological assessment and functional evaluation according to the AOFAS Ankle-Hindfoot- Score.
Results: Postoperative and follow-up radiographic imaging revealed adequate restoration of the calcaneal body. No intraoperative complications but one postoperative infection were observed. Only one secondary fusion was necessary. The mean AOFAS Score was 71.9 at a mean follow-up of 12 months.

Conclusions: Fracture care using an intrameduallary applied locking nail for calcaneal fractures showed promising results after one year in terms of reliability and safety.

OS5-39
Percutaneous stable fixation of V-metatarsal avulsion and Jones Fractures

T. Arnold[1], W. Friedl[1]. [1]*CK II, Klinikum Aschaffenburg, Aschaffenburg, Germany*

Question: The avulsion and Jones-Fractures of the 5th-metatarsal Bone are typical fractures under tension. The dislocating stress of the peroneus tendons often requires Osteosynthesis. To avoid soft tissue problems and implant failure, a percutaneous technique for reduction and fixation with a 3.5 mm compressing nail was developed.
Methods: Fracture reduction is effected with a guide wire that also serves as guidance for a cannulated 3.5 mm Drill that prepares a canal for the nail. Locking is performed using 2 mm threaded wires thru the nail. Compression of the fracture is effected by a set screw in the nail. All patients were allowed to ambulate fully weight bearing. From 7/1999 to 1/2006 77 Patients were treated with this surgical technique.
Results: The AOFAS Score pre-operatively was 22 and post OP 96. No implant failures or pseudarthrosis occurred but in 53 Patients (69%) implant removal was necessary due to local irritation by the implant.
Conclusions: The XXS Nail is a feasible method for minimally invasive and stable fixation of Fractures of the V Metatarsal with full weight bearing possibility and a low complication rate. However implant removal is indicated in most cases.

Session VI: Nail vs. plate vs. prosthesis: patella, olecranon, proximal metatarsus V, shoulder girdle and peri-implant fractures

OS6-40
Olecranon osteotomy: stable compression with the XS Nail Osteosynthesis

U. Goehring[1], W. Friedl[1]. [1]*Orthopädie, Unfall-und Handchirurgie, Klinikum Aschaffenburg-Alzenau, Aschaffenburg, Germany*

Clinical Problem: The commonly performed osteosynthesis for olecranon osteotomy show a lot of problems: the tension bend loosening and pseudarthrosis due to the soft tissue interposition, the centromedullary screw loosening in too small and fracture in too big diameter as well as dislocation of the osteotomy by self-centering and loosening of the osteotomy. Plates have the disadvantage of bulky implants under the injured skin.
Material and Methods: From 1997 on, we started to use the XS nail for olecranon osteotomy stabilization. It is a 4.5 mm straight nail which allows compression of the osteotomy due to the oval form of the proximal holes. The position for the nail is prepared with a guide wire and a cannulated drill of the same diameter before osteotomy so that after humerus osteosynthesis perfect anatomical reduction and stable osteotomy compression is achieved and no implant under the skin is present. The locking is performed with 2.4 mm threaded wires which give angular stability by being 0.2 mm bigger than the nail hole's diameter. The osteotomy is performed with a thin blade in v-shape and the part close to the articular surface is broken with a chisel.
Results: Between January 2011 and December 2015 212 patients with olecranon osteotomy were stabilized with a XS nail. In all cases physiotherapy and degree of mobilization was free regarding the olecranon osteotomy. No implant or osteotomy instability occurred. Only in one case bone grafting for delayed union was necessary. No soft tissue problems related to the olecranon osteotomy XS nail fixation occurred. Soft tissue irritation lead to partial removal of the threaded wire in three cases.
Conclusions: The XS nail osteosynthesis of olecranon osteotomy is a simple method with high stability, low complication rate and maximum soft tissue protection due to the intraosseus position of the device.

OS6-41
XS nail osteosythesis: fifteen years of experience with fractures of the olecranon and proximal ulna

U. Goehring[1], W. Friedl[1]. [1]*Orthopädie, Unfall-und Handchirurgie, Klinikum Aschaffenburg-Alzenau, Aschaffenburg, Germany*

Introduction: Fractures of the olecranon and proximal ulna are common injuries. The typical mechanism for these injuries occurs when falling on the elbow while maximal tension of the triceps muscle is present. Therefore these fractures have the tendency to dislocate, to be plurifragmentory fractured in the joint and often additional soft tissue damage occurs. Tension belt osteosythesis still is the predominantly performed surgical method for these conditions. However, high complication rates regarding dislocation, bone healing and functional outcome have been reported.
Methods: XS nail osteosythesis – which is the common procedure to be done in Aschaffenburg – is a surgical method to improve stability in these fractures. After open reduction an intramedullary nail system (diameter of 4.5 mm) locked by transversely threaded wires (diameter of 2.4 mm) are inserted proximal as well as distal to the fracture to stabilize it internally. Fracture compression is obtained by a set screw. Additional frontal or sagittal fragments can be fixed by fibre wire hemicerclages.
This presentation includes the meta-analysis of three studies from Aschaffenburg with a median follow up of three years during 1999 to 2015.
Results: Out of all 396 patients aged 16 to 98 years (mean 61 years) 32% (n = 127) had a two fragment fracture, 68% (n = 269) a three or multiple fragment fracture. Additional fractures, e.g. fractures of the radius head, were present in 8% (n = 32). Operating time was less than 60 minutes in 92% of all patients (n = 364).
In our first study from 1999 to 2002, 80 patients with olecranon fractures were treated out of which 73 patients (91%) were followed up after an average of 15 months. According to the Murphy Score, results were excellent in 47 cases (64%), good in 21 (29%), satisfactory in three (4%), and poor in two (3%). These two patients needed an operative re-intervention due to complexity of the fractures. The second study from 2003 to 2006 regarding the same pathology included 110 patients with a follow-up of three to six years which showed similar results. Identical outcome was observed in the third study from 2010 to 2015 in another 213 patients.
Conclusion: XS nail osteosythesis of olecranon and proximal ulna fractures is a surgical procedure obtaining good to very good results since more than fifteen years. We suspect this due to optimal stabilization which allows immediate functional therapy postoperatively. Soft tissue issues are rare since the lining of the fracture fragments is guaranteed by the intramedullar position of the device instead of implants on the bone's surface. For the same reason wound management is simple, if soft tissue damage is present.

OS6-42
Tension fractures of the patella: long term results of the XS nail

L. Höchtl-Lee[1], W. Friedl[1]. [1]*Orthopedic aund Trauma Surgery, Klinikum Aschaffenburg-Alzenau, Aschaffenburg, Germany*

Background and Aim: Fractures exposed to tension, such as patella fractures, have a high risk of pseudoarthrosis and dehiscence due to

their innate exposure to traction. As such, compression cannot be sufficiently exerted on the reduced fracture by the standard care of tension band wiring, owing in part to the residual interponate of soft tissue around the patella. Moreover, the eccentric position of the wire yields insufficient stability to the fracture, allowing for irregular articular surfaces during movement and consequent loss of reduction. Within seconds of application, loss of compression was found. By using an intramedullary device such as the 4,5 mm XS nail, and securing it with locking threaded wires across the entire patella, a stable fracture reduction can be achieved. With its oval holes and Allen screw, additional compression can be exerted on the fracture thus neutralizing the tension forces.
Methods: 67 Patients with Fractures of the patella treated at the Klinikum Aschaffenburg between 2002–2005 were identified from records, of which 41 could be reevaluated at a mean of 4.42 years. Clinical assessment using the Saltzman Score, as well as radiological analysis and complication recording were performed.
Results: 34 Patients (82.91%) had a Saltzman Score of 80 points (good or excellent) or better, while 5 Patients (12.19%) experienced a fair result. Only 2 Patients (4.87%) with severely comminuted and highly complex fractures scored below 70 points (poor). Two revisions, one for postoperative wound infection and postoperative hematoma were the only complications.
Conclusion: The XS nail provides a stable osteosynthesis for patella fractures without the loss of reduction even under tension. Functional, radiological and clinical results provide very good results, with excellent soft tissue protection.

OS6-43
Floating shoulder or floating shoulder girdle

A. Baltov[1], M. Rashkov[1], D. Enchev[1]. [1]*Orthopaedics and Trauma Surgery, University Emergency Hospital Pirogov, Sofia, Bulgaria*

Introduction: Apart from disruption of the classic Goss ring, injuries to two additional rings were found – one between the proximal humerus and the scapula, and one between the sternal end of the clavicle and the scapula.
Objectives: A new classification of these polystructural injuries is necessary.
Methods: For a period of 8 years 25 patients with diagnosis "floating shoulder" were operated and followed in 2 trauma level I centres in Sofia. The retrospective analysis showed that 7 patients had injuries, sustained as motorcycle driver, 7 – as car passenger, 6 – as pedestrians, 4 – as cyclist, 1 – at fall from height. Five were women with average age 45 years and 20 – men with average age 35 years. The fractures of the scapula were as follows: Fracture of the glenoid and the body of the scapula – 4; fractures of the scapular neck – 4; fractures of the scapular body – 18; fractures of the scapular spine (acromion) – 7, fractures of the coracoid – 4. The injuries of the clavicle were as follows: acromioclavicular dislocation – 4, fractures of the acromial end of the clavicle – 4, fractures of the diaphysis – 14, fractures of the sternal end – 2, sternoclavicular dislocation – 1. Fractures of the humerus were as follows: Five of the proximal part and 1 of the metadiaphysis;
Seven of the cases presented as multiple injuries, unclassifiable as floating shoulder, but as floating shoulder girdle; 3 of the patients had brachial plexus injury.
Results: We had no cases of non-union or iatrogenic vascular and neurologic trauma. All patients with floating shoulder (18) regained full range of motion – mean Constant score (CS) 88; of the patients with floating shoulder girdle 3 had acceptable, 2 good and 2 – excellent results.
Conclusions: A new classification of these polystructural injuries is necessary. We think that intra-articular gap or step-off over 3 mm and the Anavian et al. criteria for the extra-articular scapular fractures mandate ORIF.

OS6-44
Outcome after revision surgery of aseptic clavicle nonunion

C. von Rüden[1,2], J. Friederichs[2], M. Morgenstern[3], P. Augat[1], S. Hackl[2], A. Woltmann[2], V. Bühren[2], C. Hierholzer[4]. [1]*Trauma Center Murnau, Institute of Biomechanics, Murnau, Germany,* [2]*Trauma Center Murnau, Trauma Surgery, Murnau, Germany;* [3]*Traumatology, University Hospital Basel, Basel, Switzerland,* [4]*Trauma Surgery, University Hospital Zurich, Zurich, Switzerland*

Background: The purpose of this retrospective study was to evaluate the clinical and radiological outcome following compression plate fixation in combination with autologous bone grafting, with and without additional application of recombinant human Bone Morphogenetic Protein (rhBMP) for treatment of aseptic clavicle nonunion.
Patients and Methods: Between 2004 and 2015 82 patients had been treated with clavicle fracture and had developed aseptic clavicle nonunion. Seventy-three out of 82 patients were available for follow-up at least one year after revision surgery, among them 27 female and 46 male patients with a median age of 49 (range 19–86) years. Forty-five patients received compression plate osteosynthesis with autologous bone grafting, and 28 patients obtained compression plate fixation with autologous bone grafting and additional application of rhBMP-2 (3/28 patients) or rhBMP-7 (25/28 patients).
Results: Seventy out of 73 nonunions (96%) healed within 12 months after revision surgery. Functional outcome according to the DASH Outcome Measure (with rhBMP: 33.16±1.172 points, without rhBMP: 30.58±2.119 points; Mean±SEM; $p = 0.81$), nonunion healing ($p = 0.86$), time interval between revision surgery and bone healing ($p = 0.37$), and postoperative complications did not demonstrate relevant differences between the treatment groups and were not age-dependent.
Interpretation: Functional and radiological results demonstrate no trend towards improved or accelerated clavicle nonunion healing following additional application of rhBMP in combination with autologous bone grafting. In contrast, successful treatment of clavicle nonunion is dependent on radical resection of nonunion tissue, restoration of length of the shoulder girdle, and application of stable locking plate osteosynthesis.

OS6-45
Isolated, overlooked, traumatic, symptomatic scapular spine fractures

U. Kanatlı[1], T. Ayanoğlu[1], M.B. Ataoğlu[1], M. Özer[2], M. Çetinkaya[1]. [1]*Medical Faculty of Gazi University, Ankara, Turkey,* [2]*Orthopaedics and Traumatology, Necmettin Erbakan University, Meram Medical Faculty, Konya, Turkey*

The aim of this study was to evaluate the properties of patients who were treated with the diagnosis of scapular spine fractures. We evaluated 5 cases who had non-union or pseudoarthrosis of scapular spine. These fractures were the result of direct/indirect trauma as traffic accident. All of them were overlooked and symptomatic. There are few case reports of traumatic spinal fractures in the literature. But, this publication has the biggest case series in the literature.
We examined patients who were operated on with the diagnosis of a scapular fracture between 2011–2016 years in orthopaedics patient record system, retrospectively. We have reached 5 patients who had a traumatic fracture, non-union or pseudoarthrosis of scapular spine. The mean age of patients at the time of surgery was 45.8 (36–57) (2 male, 3 female). All patients were diagnosed with scapular spine non-union or pseudo-arthrosis in our Orthopaedics and Traumatology Department. The causes of these fractures were motor vehicle accidents or direct trauma. The first evaluation of these fractures were made in another hospital. On the physical examination all

patients had posterior shoulder pain. They had tenderness on the spine of the scapula with palpation and crepitation was palpable on scapular spine. There were major movements in the fracture in a patient with pseudo-arthrosis. Local anesthetic injection was used in the diagnosis of other patients. Pain reduction with a local anesthetic was support the diagnosis.

Table 1

Patients	1	2	3	4	5
Age	57	56	36	38	42
Side	Right	Right	Right	Left	Left
History	Traffic accident	Direkt trauma	Traffic accident	Direct trauma	Traffic accident
First diagnosis time	3 months	10 years	5 months	1 year	3 months
Diagnosis	Non-union	Pseudo-arthrosis	Non-union	Pseudo-arthrosis	Non-union
Treatment	Single plate	Double plate	Single plate	Single plate	Double plate
Clinical outcome	Pain free	Pain free	Pain free	Pain free	Painful
Radiological outcome	Healed	Healed	Healed	Healed	Healed
Complications	-	-	-	-	Plate irritation
Last follow-up	35 months	24 months	20 months	18 months	15 months

Table 1. Patients informations.

In the lateral decubitus position, left arm was prepared. An approximately 10 cm long incision was made parallel to the spine of the scapula. Subcutaneous soft tissues were passed and deltoid-trapezius was opened using sharp dissection. All atrophic tissue was removed with a curette until the fresh bleeding bone was reached. Then, reduction and rigid fixation were achieved by using 2.4/2.7 mm locking plate. We performed double plate system to two cases which were not stable enough. Fracture healing was checked with roentgenograms at the end of three months. If there was not a clinic or radiographic problem, patients were excluded from follow-up. At the end of six months, there were no clinical or radiological problem in any patient. Patients called for evaluation by accessing the patient information in the archive. The patients were evaluated clinically and radiologically. Only one patient had pain at the operation site. It may be due to the plate irritation. There was no pain and radiological problem in other patients (Table 1).
If we remember the possibility of a fracture or pseudoarthrosis of the spine of the scapula, palpate the posterior shoulder, and look for it on the roentgenograms, then, we do not miss the diagnosis. It is a rare fracture type, but we should not forget that it can be a reason of a painful shoulder for years. They are usually a result of a high-energy trauma; most are non-displaced or minimally displaced and treated non-operatively.

OS6-46

Filipov's method of biplane double-supported screw fixation extremely reduces the risk of fixation failure in femoral neck fractures. Clinical outcomes in 207 patients

O. Filipov[1], B. Gueorguiev[2], K. Stoffel[3], C. Sommer[4]. [1]*Vitosha Orthopaedic Hospital, Sofia, Bulgaria;* [2]*AO Research Institute Davos, Davos, Switzerland,* [3]*Universität Basel, Kantonsspital Baselland, Basel, Switzerland,* [4]*Kantonsspital Graubünden, Chirurgische Klinik, Chur, Switzerland*

Objectives: Osteosynthesis of femoral neck fractures is related to 20–46% poor results. The recently introduced Filipov's novel method for biplane double-supported screw fixation (BDSF) offers better stability by buttressing two out of three medially diverging cannulated screws on the inferior cortex with additional support on the posterior neck cortex. The two calcar-buttressed screws are oriented with steeper angles to the diaphyseal axis and with different coronal inclinations intended to provide constant fixation strength during different loading situations. The aim of this study was to evaluate the radiological results, clinical and functional outcomes from the first 5-year period of BDSF clinical application.

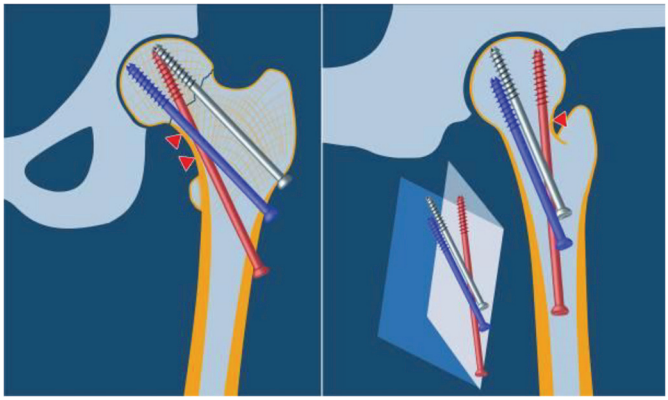

Figure 1: BDSF implements two calcar-buttressed screws, oriented in different coronal inclinations of 150–165° and 130–140°, respectively. Their medial supporting points are located 10–20 mm apart from each other, thereby distributing the axial load over a larger cortical area. The posterior cortical support is achieved by using the obtusely placed distal screw.

Methods: Subject of this retrospective study were 207 geriatric patients with displaced Garden III-IV femoral neck fractures, treated with BDSF (follow-up longer than 12 months). Three 7.3 mm cannulated screws were laid in two vertical oblique planes medially diverging towards the femoral head on lateral view. The distal screw was inserted in the dorsal oblique plane with a coronal inclination of 150–165°, whereas the middle and proximal screws were oriented in the ventral oblique plane with inclinations 130–140°. The distal and the middle screw were supported medially on the calcar and laterally at the screw entry in the diaphyseal cortex. The distal screw had additional third supporting point on the posterior femoral neck cortex. The investigated radiographical, clinical and functional outcomes in the study were related to patients age, gender, comorbidities, mobility, fracture displacement stage (Garden III or IV), bone union, nonunion (pseudoarthrosis or fixation failure), AVN, Harris hip score-modified, pain and handling socks and shoes skills.
Results: The outcomes in 207 patients were analyzed in 29.6±16.8 months follow-up. Patients age with fracture consolidation (76.1±9.9) or with Garden III fractures (73.9±9.5) was lower compared to patients with fixation failure (82.2±7.3) or with Garden IV fractures (76.4±9.9), respectively, $p \geq 0.21$. Bone union occurred in 96.6% of the cases (males 97.6%, females 96.4%, $p = 1.00$). Rate of nonunion was 3.4%, including fixation failure (2.4%), pseudoarthrosis (0.5%) and nonunion with avascular necrosis (AVN, 0.5%). Rate of AVN was 12.1% (males 4.8%, females 13.9%, $p = 0.12$). Harris hip score-modified was higher for males (89.3±18.1) versus females (85.4±19.1), $p = 0.07$. Age of patients declaring good mobility (75.4±10.2) or easy shoe handling (75.1±10.1) or with less than 1 comorbidity (55.8±3.4) was significantly lower compared to patients with poor mobility (80.8±5.9) or difficult shoe handling (81.3±6.7) or with more than 2 comorbidities (76.7±9.5), respectively, $p < 0.01$.
Conclusions: By providing additional cortical support, the novel BDSF method enhances femoral neck fracture fixation strength, reveals excellent clinical outcomes and extends the indications for internal fixation when osteoporosis is present.

OS6-47

Peri-implant femoral fractures: the risk is more than three times higher within PFN compared with DHS

F. Müller[1], M. Galler[1], B. Füchtmeier[1]. [1]*Clinic for Trauma and Orthopedic, Hospital Barmherzige Brüder, Regensburg, Germany*

Question: Information is lacking regarding incidence rates, treatment regimens, and outcomes concerning peri-implant femoral fractures (PIF). Therefore, we performed a retrospective study to provide scientific data concerning incidence and outcome of PIF following osteosynthesis of proximal femoral fractures (PFF).
Methods: We retrospectively included all patients who received osteosynthesis for PFF between 2006 and 2015 and in whom PIF was confirmed postoperatively. All available patients with PIF were contacted minimum one year post-surgery.
Results: A total of 1,314 osteosynthesis procedures were performed, of which 705 were proximal femoral nails (PFNs), 597 were dynamic hip screws (DHSs), and 12 were screws appliances only. During the same period, 18 PIFs (1.4%) were reported. However, PIF was 3.7 times higher within PFN when compared to DHS (15/705: 2.1% versus 3/597: 0.5%; odds ratio: 3.7). The following analysis also included 8 patients with PIF who were referred from other hospitals, resulting in a total of 26 patients. Mean patient age was 84.8 years (range, 57–95), with a predominance in female (23×) and in the left femur (19×). PIF occurred after an average of 23.6 months (range, 1–81) post-surgery. The fractures, most of which were spiral-shaped, were most commonly treated with locking plate osteosynthesis. The surgical revision rate was 7.7%, and the one-year mortality was 23.1%. At an average of 43.0 months (range, 12–100) post-surgery, it was possible to contact 18/26 patients (69.2%), and their mean Parker Mobility Score was 5.2 points (range 2–9).
Conclusions: Peri-implant femoral fracture is a rare incident within the old age traumatology of PFF. However, based on our small number of cases, it occurred within PFN much more frequently compared with DHS. Locking plate osteosynthesis has been shown to be effective and reliable. Surgical revision and mortality rates do not appear to be increased when compared to those with the initial treatment of proximal femoral fractures.

OS6-48

Peri-implant femur fractures after short hip nailing: the impact of non-locked nails

J. Skala-Rosenbaum[1], V. Dzupa[1], P. Dousa[1], R. Bartoska[1]. [1]*Orthopedics and Traumatology, FNKV, Charles University, Prague 10, Czech Republic*

Question: The most common cause of femoral fractures after osteosynthesis of trochanteric fractures with short nails is weakening of the femoral cortex via distal locking and stress concentrations at the tip of the nail. The aim of the study was to verify whether the incidence of peri-implant fractures is dependent upon the distal locking technique.
Methods: We prospectively analyzed a group of 849 pertrochanteric fractures (AO/ASIF 31-A1+2) managed with short nails from 2009–2013. Unlocked nailing was performed in 70.1% and distal dynamic locking was performed in 29.9%. The mean age was 82.0 years. Peri-implant fractures were divided into 3 groups according to the height of the fracture in relation to the tip of the nail.
Results: In total 17 fractures (2.0%) were analyzed. One peri-implant fracture occurred after locked nailing, whereas 16 cases occurred after unlocked nailing ($p = 0.037$). Patients without distal locking had an 85.7% greater risk of peri-implant fracture. Fractures of the proximal femur (Type I) occurred significantly earlier than fractures at the tip of the nail (Type II) ($p = 0.028$).
Conclusions: Unlocked nails do not guarantee sufficient stability. Distal locking is not the cause of peri-implant femur fractures, but it rather serves to prevent postoperative femoral fractures. We recommend the routine use of distal locking when utilizing short nails.

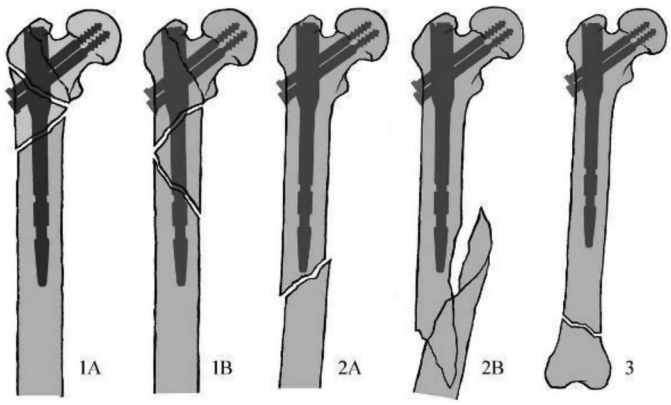

Figure 1:

Session VII: Today's place of ExFix fracture management in primary care, definitive treatment and complication management

OS7-49

Indication and techniques of distal radius fixation with plate, nail and ExFix

G. Gradl[1], N. Mielsch[1], M. Wendt[1], S. Falk[1], T. Mittlmeier[1], P. Gierer[1], G. Gradl[2]. [1]*Department of Trauma- and Reconstructive Surgery, Surgical Clinic University of Rostock, Rostock, Germany,* [2]*Department of Trauma and Reconstructive Surgery, Aachen University Medical Center, Aachen, Germany*

Background: Several techniques for stabilization of displaced distal radius fractures are available. Palmar plating, im nailing and extra articular external fixation all provide the possibility of early functional after treatment. Purported benefits of these technique include limited soft tissue dissection while affording sufficient stability.
The goal of this study is to detect differences among these treatment modalities with respect to functional outcome, pain and disability.
Methods: This is a single-centre, multiple-group trial, with unrestricted randomization between either plate fixation versus intramedullary nailing (study I) and plate fixation versus external nonbridging fixation (study II). Patients with dorsally displaced extra-articular distal radius fractures were randomized to receive plate osteosynthesis (PO, $n = 72$) or intramedullary nailing (IM, $n = 80$) (study I). In study II 52 patients were randomized for PO, 50 patients (EF) received nonbridging external fixation (AO small fixator). The outcome was measured on the basis of the Gartland and Werley and Castaing score; the pain level; the range of wrist motion; the rate of complications; and radiographic measurements including volar tilt and ulnar variance. Clinical and radiographic assessment was performed at 8 weeks, 6 months (study I, II), and 1 year and 2 years after the operation (study I).
Results: Study I revealed no significant differences between groups in terms of range of motion, grip strength or the level of pain during the entire follow-up period ($p > 0.05$). There was no significant difference between treatment groups with respect to volar tilt or ulnar variance ($p > 0.05$). There was no significant difference in the complication rate between groups ($p > 0.05$).
Study II radiological evaluation did not detect excessive loss of radial length >3 mm in any group. The palmar tilt was better restored by external fixation (7.2°) than by palmar plating (0.1°). A good wrist function was achieved in both groups, however 8 weeks after surgery, the grip strength was more reduced in the EF-group (27% of uninjured side) than in the PO-group (51%). The external fixator was tolerated

very well, and the quality of life assessment revealed comparable results in both groups.
Conclusions: The present study suggests that intramedullary nail fixation and volar plate fixation for the treatment of displaced extra-articular distal radius fractures have equivalent radiographic and functional outcomes. External nonbridging fixation has no drawback in terms of anatomical restoration.
Level of Evidence: Level I therapeutic study

OS7-50
Minimal-invasive treatment of adolescent proximal fractures of the tibia by external fixation

H. Jansen[1], K. Fehske[1], M. Jordan[1], R. Meffert[1]. [1]*Unfallchirurgie, Universitätsklinikum Würzburg, Würzburg, Germany*

Fractures of the proximal tibia in the adolescent are rare but challenging. Common treatment includes K-wires with and cast without functional aftercare or plate osteosynthesis with the disadvantage of an extended operative procedure. Treatment with a rigid external fixator combines the advantage of a minimal-invasive procedure and early functional care.
We report on three adolescent males (1 × 13 years, 2 × 16 years) with open growth plates and proximal fractures of the tibia (2 × Salter-Harris-II, 1 × Triplane) who were treated with an external fixator in the sagital plane.
All three planes healed without complications. Function was not compromised compared to the uninjured side.
Treatment with an external fixator in fractures of the proximal tibia in the adolescent is a safe and minimal-invase treatment option.

Figure 1:

OS7-51
Software-based Ortho-SUV Frame in children long-bone deformities correction: analysis of 162 cases

V. Vilensky[1], P. Alexander[1], Z. Ekaterina[1]. [1]*Bone Pathology, The Turner Scientific and Research Institute for Childrens Orthopedics, Saint-Petersburg, Pushkin, Russian Federation*

The Aim of the Study: To analyze the efficiency of computer-assisted Ortho-SUV Frame (O-SUV) in treatment of long bone deformities in children treated in the Turner Research Institute for Children Orthopedics, Saint-Petersburg, Russia.
Methods: Ortho-SUV Frame (Pitkar Pvt. LTD, India; Ortho-SUV Ltd., Russia) is one of the software-based external fixators working in the field of 6-axis deformity correction. According to the classification of long bone deformities (http://www.ortho-suv.org/images/stories/deform_class2.jpg) 24 cases had simple deformities (SD), 54 cases – deformity of middle complicity (MD) and 84 cases – complex (CD). The results are evaluated on the following parameters: a period of deformity correction (DCP), external fixation index (EFI), accuracy of deformity correction (AC), the number of complications. To assess the AC we used reference lines and angles.
Results: O-SUV was used in 162 cases (197 frames). Most of children had congenital deformities (86), aquired deformities (51) and 25 had posttraumatic deformities. Found DCP was 11.2±8.4 days for SD; 14.6±7.42 for MD and 20±15.3 for CD. EFI for SD was 30.2±16.2 days/cm, for MD – 33.6±13.4 and for CD – 36.2±14.1. AC for deformities in frontal plane was 92.5% and for deformities in sagittal plane – 90.1%. The reached MAD in varus (valgus) deformities were 1.3 + 7.4 (2.2 + 6.5). Reached mMPTA in varus (valgus) deformities was 86.3 + 6.6 (90.4 + 7.2); mLDTA – 91.1 + 5.8 (88.2 + 6.2). In procurvatum (recurvatum) deformities reached PPTA was 80.2 + 3.4 (81.3 + 2.4), ADTA – 82.3 + 7.2 (80 + 6.6). We faced with the following complications (%): pin-tract infection – 16; joint contracture – 17; breakage of transosseous elements – 3; non-union or atrophic regenerate formation – 3; secondary fractures and deformities – 6.
Conclusion: High accuracy and short terms of deformity correction provided by O-SUV is good background for its further use in pediatric orthopedics.

OS7-52
Treatment of femur osteomyelitis with shortening in tree steps and usage of both external fixators and internal fixator

M. Akdemir[1], M.A. Türken[1], A. Arıkan[1], A. Erbay[2], A.C. Turan[1], A. Biçen[1], A. Ekin[1]. [1]*Orthopaedics and Traumatology, Izmir University Faculty of Medicine, Izmir, Turkey,* [2]*Infectious Diseases and Microbiology, Izmir University Faculty of Medicine, Izmir, Turkey*

Question: Femoral osteomyelitis with a nonunion is a challenging problem for both patient and orthopaedic surgeon. The treatment steps are; taking the control of the infection and achieving union. But on the other hand, the most important problem for the patient is limp length discrepancy. To solve this problem external fixators were recommended. But these devices are poorly accepted by the patients. In this study we want to introduce our three step treatment system; external fixator- debridement, osteotomy, external fixator removal and internal fixator (all-locking screw long plate).
Methods: There was 4 patients in our study. All were men. Average age was … years. Two of them had gunshot injury and one had open fracture, one infection after intramedullary nail. Duration of the osteomyelitis were ten years for two, three years and 3 months. Staphlococuc aureus (methicillin resistant) for two, and acinetobacter baumanii were the pathogens. One patient's culture was negative. 3 had fistulas, 1 had no fistula.
At first, we made femoral shortening and radical debridement of the osteomiyelitis, than we prefer external fixator for fracture fixation (3 rail, 1 circular). We did not use any bone graft. We made bone

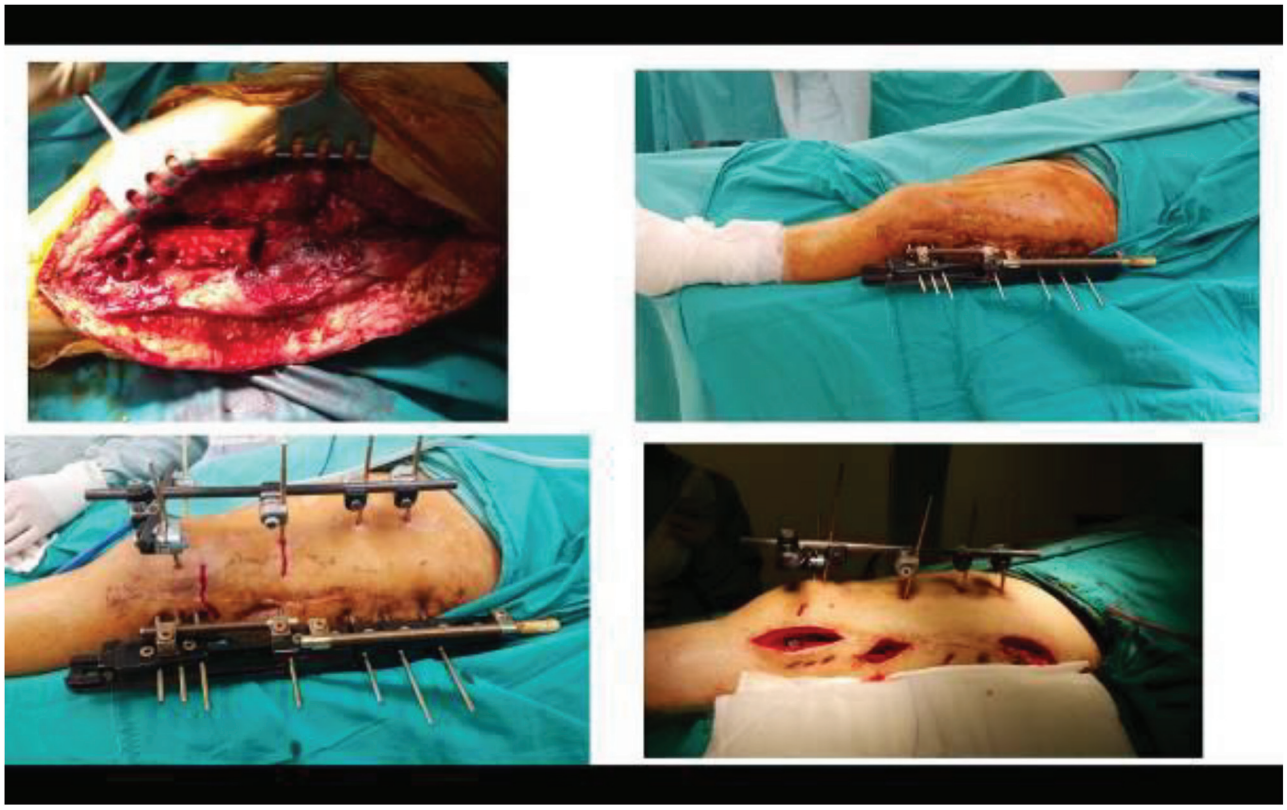

Figure 1: (abstract: OS7-52)

resection until the bleeding bone ends. By the external fixator, compression over the fragments was made. After the control of the infection, we did femoral osteotomy over the external fixator and lengthening was started. After enough lengthening was achieved, we stopped the lengthening. Approximately 1–2 months waited for bone cloud at the regenerate area. After that we planned the third operation. We applied a temporary second external fixation anteriorly to protect limp length, regenerate and compression over the nonunion area. We removed the lateral external fixator which we applied before and with percutaneous technique, we applied a long lateral locking femoral plate as internal fixator. After then antero-lateral temporary external fixator was removed.

After external fixator removal, patients were encouraged to give weight as much as they could. Active knee and hip exercises was started.

Results: All four of the patients had union for average 17 (12–20) months. There was no recurrence of infection.

The average femoral shortening before the operation was 5.5 cm. during the operation, an average 6.6 cm of bone was resected. Lengthening over the osteotomy site was 10.9 cm. shortening at the end of the treatment was 1.3 cm.

2 of the 4 patients has pin tract infection and treated with oral antibiotics. There was no any wound problem and deep infection of bone and soft tissues.

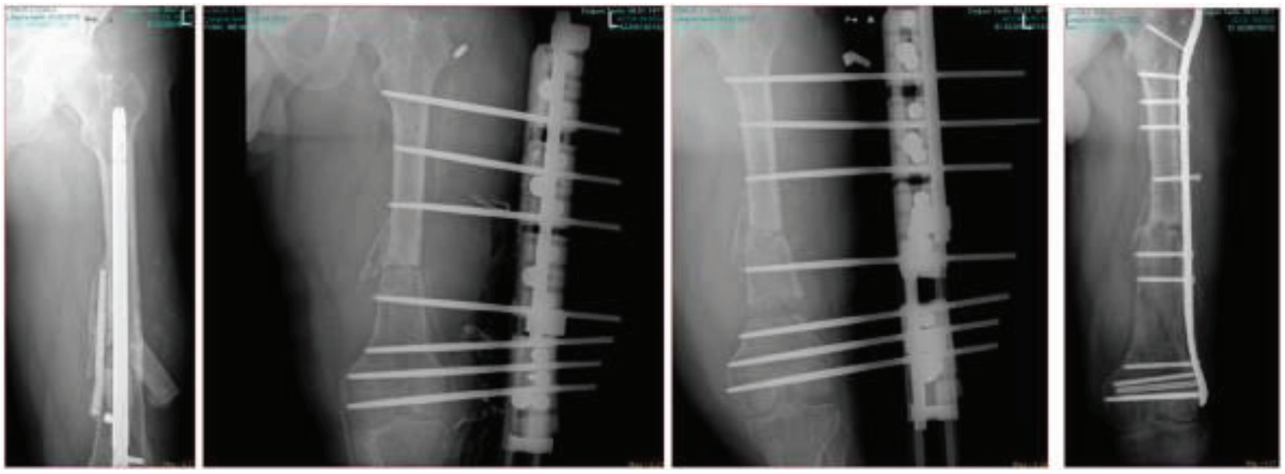

Figure 2: (abstract: OS7-52)

One patient has plate breakdown with inadequate regenerate formation, treated by plate removal and application of double plate and with iliac crest autografting. This patient had union of both fracture site and osteotomy site.
Conclusions: Treatment of femoral osteomyelitis with tree steps is a good treatment strategy with relatively low complications in our small series. Also application of temporary external fixator during the external fixator-rail system removal and is a good option to protect length and reduction of the fracture site.

OS7-53
Multiplanar external fixation in tibia open fractures (by using a couple of external fixators)

B. Gogulescu[1]. [1]*Orthopedic and Trauma, Clinical Emergency Hospital, Galati, Romania*

Introduction: High-energy injuries are becoming more common. Open tibial fracture incidence is increasing. Subcutaneous location of the tibia and type of blood circulation in the calf creates additional risks compared to other regions.
Purpose: This study represents a retrospective analysis of the ose of external fixation of comminuted fractures in treatment of tibia open comminuted fractures.
Methods: Between 2012 and 2015, for 43 patients with an average age of 47 years of age (range: 27–29 years) was performed a tibial reconstruction in Emergency for treatment of open multifragmentation fractures of the tibia. There were used two fixators in two different plans (84% of cases). The average duration of follow-up was 24 months, by evaluating functional radiological results.
Results: The average period of immobilization by using external fixator was 4 months (one month to 16 months).
In three cases, fractures were bilateral. There were 21 excellent results, 12 replacements of intramedullary rod fixator, 5 misalignments resolved through replacing, 3 pseudarthrosis, an osteosynthesis in order to achieve a presentable blunt and a post ischemic amputation.
Conclusions: Using a couple of external fixators is an efficient and reliable method to treat open tibial fracture multifragmentation in emergency cases. Each patient must be evaluated in Emergency in terms of preserving or restoring vascular axis and in terms of the possibility of a viable skin coating. Multiplanar fixation (of minimum two fixators) of multifragmentation tibial fractures provides stability in terms of a viable bone tissue that confers strength by providing a solid contact to the pins. This enables early mobilization. Resumption depends on solid junction of the tibia and fixator. In our assessment, using tapered pins (to the bone) and an assembly of two fixators or those in the arch, provides a robust architecture that definitely influence tolerant and functional outcome. Soft tissue care is easy and safe.

OS7-54
The special entity: implant-associated, chronic, destructive osteomyelitis of the humerus. Complex therapy options and outcome

T. von Stein[1]. [1]*BG-Trauma-Center Murnau, Septic & Reconstructive, Murnau, Germany*

Question: Is a standardized therapy for a humerus osteomyelitis feasible? What options exist for reconstruction? What is the outcome, specifically the function? Do risk factors, respectively comorbidity play a role?
Methods: Between 2004 and 2014, 10 patients with chronic, partly highly destructive osteomyelitis of the humerus shaft and the distal humerus were treated in our clinic. The patients' age was between 22 and 83 years, averaged 43 years. With every patient the primary osteosynthesis and the germ-ridden segments had to be removed. Ensuing were several stages of debridement, the appropriate antibiotic therapy and individual construction in case of negative bacteriology. With 3 patients the elbow joint was involved.
Results: 3 Patients originally had an open fracture. With 7 patients the germ was a multi-resistant, coagulase negative staphylococcus, 2 MRSA, 2 enterococcus faecalis and enterobacter cloacae. The time period between initial diagnosis and reconstruction after decontamination was between 3 months and 21 years, post-operative observation lasted between 6 and 48 months. Up to definitive reconstructions between 5 and 37 surgeries were required. All 3 endoprosthetic attempts to reconstruct the elbow joint failed, two ended in a sine-sine-situation (one of them with very good function), one in an arthrodesis. 5 patients received a free, vascular pedicled fibula transfer. 4 patients suffered from a persistent lesion of the n. radialis, 2 from persistent lesion of the n. ulnaris. In the end the function was in 4 cases good, in 3 cases moderate and in 2 cases significantly restricted. A correlation with risk factors such as age and previous disease could not be determined.
Conclusions: The chronic osteomyelitis of the humerus following a surgically treated fracture is a rare, but most severe complication. The risk of a nerval lesion is extremely high and the resulting function essentially dependent thereof. In every case a very individualized therapy and highly complex reconstruction was necessary, which only seems feasible in a center with micro-surgery and extensive experience in septic surgery. The possibility of a standardized therapy could only be seen regarding decontamination.

Session VIII: Complication management after infection and pseudarthrosis

OS8-55
Use of Masquelet technique in treatment of septic and atrophic non-union

A. Moghaddam[1,2], C. Ermisch[1], G. Schmidmaier[1]. [1]*Trauma Surgery and Spinal Cord Injury, University Hospital Heidelberg, Center of Orthopaedics, Heidelberg, Germany,* [2]*Trauma Surgery and Spinal Cord Injury, University Hospital Heidelberg, Center of Orthopedics, Heidelberg, Germany*

Question: The successful treatment of atrophic non-unions with large bone defects or infections still is a major challenge in orthopedic and trauma surgery. A new therapeutic concept is the two-step procedure "Masquelet technique" according to the "diamond concept".
Methods: Between February 2010 and February 2015, 150 patients (50 female, 100 male) with atrophic non-unions treated in a two-step procedure among Masquelet technique according to diamond concept were included in this prospective study. Clinical and radiological parameters were measured preoperatively as well as 4, 6 and 12 weeks, 6 and 12 months postoperatively. We used the SF-12 questionnaire to evaluate the subjective health of patients. Data analysis was conducted at least one year after treatment.
Results: A successful bony consolidation of the non-unions was observed in 120 (80.0%) cases with a median healing time of 12.1 months (SD 7.9; Min 3.7 – Max: 58.7). The mean defect gap was 4.4 cm (SD 3.6; 0.5–26.0 cm). Osteitis was documented in 54 (35.8%) cases, whereby most germs 37 (68.5%) were located at the lower leg, 14 (25.9%) at the femur and 3 (5.6%) at the upper arm bone. The most frequently identified germs were Staphylococcus epidermidis (17 out of 54 cases) and Staphylococcus aureus (11/54). A successful eradication of germs with following consolidation was achieved in 39 cases (72.2%). In 96 cases without detected germs a consolidation of 81 patients (84.4%) could be achieved. In SF-12 questionnaire determined scores of subjective physical and mental health increased from PCS 31.5 (SD 8.5; 14–55.7) preoperatively to 36.7 (SD 10.3; 16.9–56.6) one year postoperatively as well as MCS from 45.5 (SD 11.4; 21.7–67.1) to 48.7 (SD 12.1; 22.3–68.3).

Conclusions: The Masquelet technique as a two-step bone grafting method according to the diamond concept is a promising option especially for the treatment complex cases with large bone defects and infections,- combining a high patient's comfort with a controlled opportunity of germ eradication.

OS8-56

The epidemiology of fracture nonunion in 18 human bones: analysis of a payer database of ~90.1 million patients

R. Zura[1], Z. Xiong[1], T. Einhorn[1], J.T. Watson[1], R.F. Ostrum[1], M.J. Prayson[1], G.J.D. Rocca[1], T. Mehta[1], T. McKinley[1], Z. Wang[1], R.G. Steen[1]. [1]*Louisiana State University Health Science Center, New Orleans, United States*

Introduction: The rate of nonunion is generally accepted as 5–10% of all fractures [1]. We hypothesize that biological risk factors assessable at patient presentation can be predictive of fracture nonunion.
Methods: Patient-level health claims for medical and drug expenses were compiled for approximately 90.1 million patients. Study inclusion was limited to patients with a coded bone fracture in calendar year 2011, with continuous enrollment for 12 months after fracture, to allow sufficient time to capture a nonunion diagnosis. The final database had 257 patient variables for each fracture. Variables included demographic descriptors, treatment procedures as per Current Procedural Terminology (CPT) codes, co-morbidities as per International Statistical Classification of Diseases and Related Health Problems (ICD-9) codes, and drug prescriptions as per National Drug Code Directory (Red Book) codes. Logistic regression (SAS) was used to calculate odds ratios (ORs) for variables associated with nonunion. This study was exempted from ethical approval by the Institutional Review Board of Duke University Medical Center because patient data were completely de-identified.

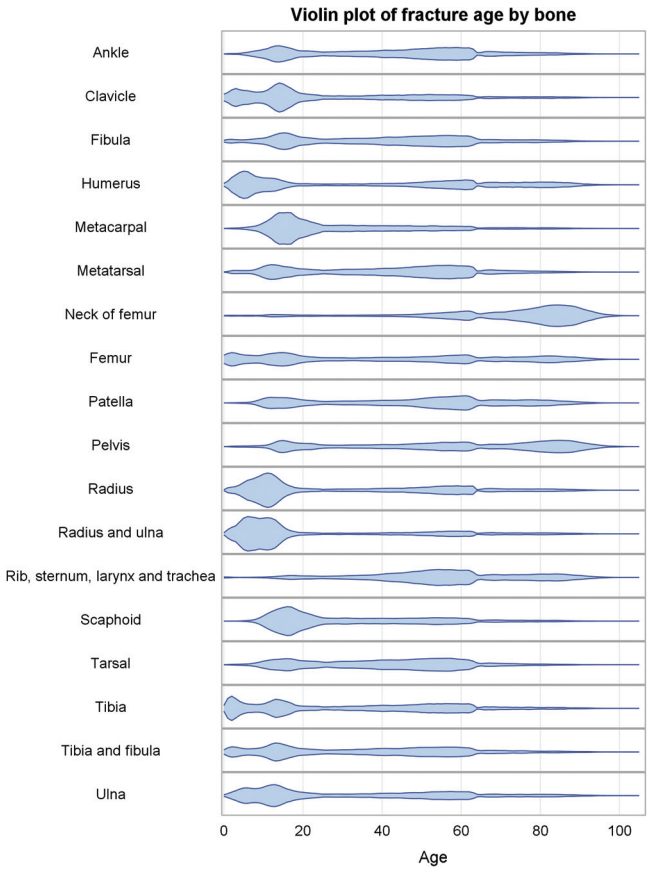

Figure 1:

Results: Among 313,256 fractures in 18 bones, the nonunion rate was 4.7%. Certain bones were more likely to fracture in patients under age 20 (figure below), while other bones were likely to fracture in patients over age 65; surprisingly, certain bones were more likely to fracture in patients aged 20 to 65 years. Elevated nonunion risk was associated with open fracture, multiple fractures, high body-mass index, smoking, and alcoholism. Females had more fractures, but males were more prone to nonunion. Multivariate ORs for nonunion are generally small.
Discussion: Nonunion is a function of fracture severity, location, and morbidity (SLAM). The interplay of risk factors is complex, but it should become possible to predict nonunion. Medications have a significant impact on fracture nonunion and can potentially be altered to improve healing.
Significance: Fracture severity, location, and morbidity (SLAM) can potentially be incorporated into a predictive algorithm that may help clinicians determine which fractures are at greatest risk of nonunion. Patient medications are unusual in that they have a significant impact on fracture healing and can potentially be stopped or adjusted by a physician after fracture to improve healing.

References

[1] Zura R, Mehta S, Della Rocca G, Steen RG, Biological risk factors for nonunion of bone fracture. *JBJS-Rev*, 2015 (in press)

Disclosures: All authors have worked for Bioventus, either as consultants or employees.

OS8-57

Deformity correction and intramedullary nailing: indications and limits

F. Wolf[1], J. Fürmetz[1], T. Eilers[1], P.H. Thaller[1]. [1]*Department for General-, Trauma- und Reconstructive Surgery, 3D Surgery, Medical Center of the University of Munich, Munich, Germany*

Objectives: Intramedullary nailing is the gold standard for many types of fractures of the lower extremity. Nevertheless, intramedullary nailing is rarely used for osteosynthesis after correction osteotomies. A retrospective analysis of clinical cases was performed, to analyse indications and limitations for intramedullary nailing in deformity correction.
Materials and Methods: Cases were collected between 07/2009 and 02/2016 out of all osteotomy procedures with acute correction and internal fixation. In all cases, detailed preoperative analysis and planning was performed. Deformities were classified according to their prevalent morphology as diaphyseal, metaphyseal or torsional. Mean correction amount and deviation of the postoperative result in comparison to preoperative End-Point-First-Planning were calculated. An early clinical follow up was conducted.
Results: A total number of 47 procedures of deformity correction at the lower limb with use of intramedullary nails was found. Intramedullary nails were applied in following approaches and number: femur antegrade (fa): 7, femur retrograde (fr): 10, tibia antegrade (t): 29 and humerus antegrade (ha): 1. Only minor deviation of postoperative results to preoperative planning was detected. The clinical follow up showed early full weight bearing. Adverse effects related to the use of intramedullary nails have not been seen.
Conclusion: Intramedullary nails are suitable for deformity correction of femur and tibia, if plating is a less valid option. Deformities that have their CORA (Center of Rotation and Angulation) in the diaphyseal part of the bone are ideal for intramedullary nailing after correction osteotomy. Metaphyseal deformities can be treated by nailing as well, if precise preoperative planning and special techniques like blocking screws are used. Bending of intramedullary nails and the use of rigid reamers are an option, but require special equipment and knowledge. Retrograde nailing of the femur is a good option, if the transarticular approach is performed minimally invasive.

OS8-58
Bone transport for bone defects: how to face the big gap

F. Wolf[1], P. H. Thaller[1], J. Fürmetz[1]. [1]*Department for General-, Trauma- und Reconstructive Surgery, 3D Surgery, Medical Center of the University of Munich (LMU), Munich, Germany*

Objectives: Transport of bone segments is a principle for closing segmental bone defects by distraction osteogenesis. It can be used for the treatment of defects that are caused primary by trauma or for those, which are generated secondary after bone resection because of infection or tumor. Since the method is rarely applied, an overview of practical technique and its clinical outcome is given.
Materials and Methods: A multicenter based review of a total of 30 bone transport cases was performed. Various techniques of external fixation were used in the collective: Ilizarov ring fixator, hybrid fixator and monolateral fixators. Innovative technical details, like a cable system for bone transport or custom made solutions in external fixation are described in detail.
Results: Segmental bone defects can be treated successfully by bone transport. Criteria for an uncomplicated treatment course could be figured out. Length of primary defect and degree of primary soft tissue damage and contamination have lesser negative influence on the outcome, than suspected. Early soft tissue coverage by plastic surgery seems to have positive influence on the outcome. The technique of bone transport can be combined with other principles like further lengthening after docking or minimally invasive internal fixation for shorter external fixation time.
Conclusion: Bone transport is a surgical principle that can provide solutions for limb salvage. Meticulous planning of the treatment course is a key point for success, especially in the management of concomitant soft tissue problems.

OS8-59
Predictors of non-union and infectious complications in patients with post-traumatic subtalar arthrodesis

S. Dingemans[1], M. Backes[1], C. Goslings[1], V. de Jong[1], J. Luitse[1], T. Schepers[1]. [1]*AMC, Trauma Unit, Amsterdam, Netherlands*

Introduction: Subtalar arthrodesis can be used either as a primary procedure or as a secondary salvage procedure following a trauma of the hindfoot. Both the primary and the secondary arthrodesis are technically demanding procedures and even in experienced hands high complication rates have been reported. The aim of the current study was twofold: 1) to identify predictors of both non-union and postoperative wound infections (POWI) and 2) to assess the union- and complication rate following post-traumatic subtalar arthrodesis (STA).
Methods: All consecutive adult patients with subtalar arthrodesis following traumatic injuries between 2000 and 2014 from a level 1 Traumacenter were retrospectively analyzed. Patient, injury and surgery characteristics were collected. Outcome measures were (non-) union and POWI.
Results: A total number of 93 (96 feet) patients met the inclusion criteria. Union was achieved in 89% of patients. For primary, secondary in situ and secondary correction arthrodesis these percentages were 94%, 84% and 90% respectively (NS). The union rate significantly increased over time ($p = 0.02$). In 17 patients (18%) a POWI occurred, of which two were classified as superficial and fifteen as deep POWI's. The POWI rate did not differ between the groups. Alcohol, nicotine and drugs abuse were not significantly associated with the occurrence of POWI's. Patients with an open fracture or an infection following primary treatment had a greater risk of POWI ($p = 0.03$ and $p = 0.04$ respectively).
Conclusion: We could not identify predictors for non-union. In 18% of the patients an infectious complication following surgery occurred. Patients with an open fracture or an infection following primary surgical treatment have a higher chance of POWI's following STA. The union rate following posttraumatic subtalar arthrodesis is 89%.

OS8-60
Avoiding cardiovascular complications of cement: cementless hemiarthroplasty for femur neck fractures. A fall-control study to evaluate intraoperative cardiorespiratory changes due to cement use

A. Terzis[1], W. Friedl[1]. [1]*Klinikum Aschaffenburg, Aschaffenburg, Germany*

Question: Patients with femur neck fractures are getting older and more multimorbid. We observed at our clinic an increase of severe complications at the point of the insertion of the cemented stem. Hence we use since 2010 only cementless stems for the treatment of such fractures. Aim of the study was to investigate if the use of cementless stems can reduce the risk of cardiopulmonary complications as well as the postoperative treatment at the intensive care unit and the intra- and postoperative mortality rate.
Material and Methods: Two groups A and B were examined, each one including 50 patients, group A patients were treated with cemented stem, group B cementless. The parameters examined included age, gender, ASA score, RR and CO_2 decrease, ICU stay, mobility grade, blood transfusion and mortality rate.
Results: It could be shown that in the group of cementless stem the complication rate was significantly lower for intraoperative CO_2, O_2, RR decrease, ICU stay and mortality rate. This group showed a slightly higher blood transfusion rate postoperatively compared to the cemented stem group. The mortality rate of the cemented stem group was 14%, 10% of which occurred within the first week postoperatively. The mortality rate within the cementless group was 6%, during the first postoperative week 0%. 26% of the patients of group A had a longer ICU stay postoperatively, only 12% of the patients of group B needed an ICU treatment.
Conclusion: Embolisation of the bone marrow leading to cardiopulmonary embolism can be significantly reduced by avoiding the use of cement. The mortality rate postoperatively as well as the ICU treatment was reduced up to 50%. The early mortality rate within the first week postoperatively was reduced from 10% to 0%.

OS8-61
Dead space management in intramedullary infections

F. Wolf[1], J. Fürmetz[1], S. Patzler[1], P.H. Thaller[1]. [1]*Department for General-, Trauma- und Reconstructive Surgery, 3D Surgery, Medical Center of the University of Munich (LMU), Munich, Germany*

Objectives: Infection of the cavity of long bones usually occurs after open fractures, perforating injuries like gunshot wounds or as a complication after intramedullary nailing. Surgically demanding problems besides the infection are instability and the situation of "dead" space in the intramedullary cavity, which is isolated from immunologic and antibiotic influence.
Materials and Methods: A case series of 5 patients with infection of the intramedullary cavity was reviewed in detail. In this group novel surgical techniques were applied: approach to the medullary with special steel sleeves to prevent dispersion of infected debris during debridement, cleaning by use of rotating brushes and the so called "kite tail technique" for directed positioning of resorbable antibiotic sponges along the medullary cavity.
Results: In all patients of the above mentioned case series, infection could be treated successfully by one surgical procedure. Mean time of treatment in the hospital was 12 d (range 8–20 d). Besides the local antibiotics, a systemic and tested antibiotic therapy was administered for an average of 46 days (range 18–89 d). Complications related to the method did not occur. Experiences from the case series and review of existing literature lead to a structured algorithm for the treatment of medullary infection.
Conclusion: Successful treatment of intramedullary infection requires an individual strategy for every single case. Debridement

and dilution of bacterial load, local antibiotic therapy and temporary or definitive stabilization have to be combined to a treatment plan without creating conflict between the particular principles.

OS8-62
The results of bone grafting in the management of poor regenerate formation during lengthening with lengthening nails

M.F. Erol[1], B. Abay[2], O. Karakoyun[1], M. Kücükkaya[2]. [1]*Orthopedics and Traumatology, Namik Kemal University, Tekirdag, Turkey,* [2]*Orthopedics and Traumatology, Istanbul Bilim University, Istanbul, Turkey*

It is not so common to see poor regenerate formation in lengthening with lengthening nails. Between years 2008–2016 sixty-three bone segments were lengthened with lengthening nails (25 Fitbone, 27 Pricece, 12 ISKD). Among them poor regenerate formation at the lengthening site were observed in 6 bone segments (5 femur, 1 tibia) of 5 female patients. The mean age of the patients was 18 (14–36) years. Two of the patients were ISKD and 3 of them were Fitbone cases. The reason of poor regenerate formation were "run away" phenomenon in 2 cases in which ISKD nails were used for lengthening. One of the Fitbone cases was a heavy smoker. In the rest 2 Fitbone cases the femurs were too thin and it was necessary to ream the medullary canal excessively for the insertion of the Fitbone nail which do not has the option of suitable small nail diameter. The defects were greater than 4 cm in 2 cases while the others were less than 4 cm. The management method of this situation was graft application to the poor regenerate sites. The spongious graft reserve of an average iliac bone is approximately 20 cc. In cases of the cortical segmental defects of greater than 4 cm the autogenous graft reserves of the patients are not sufficient. We prefer spongious autografts for the management of the defects lesser than 4 cm in 4 cases. The other 2 cases with defects greater than 4 cm were managed by using sandwich technique in which spongious and strut grafts were used. We managed successfully all 6 bone segments with poor regenerate formation. The graft integration was achieved in each case without any additional intervention. Autologous spongious bone grafting is a sufficient in cases of poor regenerate formation during lengthening with lengthening nails when the defect is less than 4 cm. In cases with a defect of 4 cm sandwich method is suitable for the management of poor regenerate formation in the use of lengthening nails.

OS8-63
The importance of reaming the posterior femoral cortex before inserting lengthening nails and calculation of the amount of reaming

M. Kücükkaya[1], O. Karakoyun[1], M. F. Erol[1]. [1]*Orthopedist, Istanbul, Turkey*

Question: Lengthening nails have been used to correct limb length discrepancy caused by different etiologies. Two important lengthening nail-related complications are damage to the distraction mechanism and femoral fractures around the nail tip. As a result of the curved anatomy of the femur, straight nails impinge on the anterior cortex. Therefore, proper reshaping of the medullary canal to accommodate straight lengthening nails is crucial for the prevention of this problem. Reaming the dense posterior cortex is important when aiming to insert a lengthening nail without incurring anterior cortex nail tip impingement-related complications. Posterior femoral cortex over-reaming is a solution to this situation.
Methods: Sixty patients received lengthening nails during 2008–2013, (ISKD, Fitbone, Precice). Posterior cortex rigid-reaming technique was used successfully in 45 retrograde femoral lengthening cases. The preoperatively planned posterior cortex amount was reamed until the impingement was overcome during the operation under fluoroscopic control for each case. Since the preoperative determination of posterior cortex reaming amount is time consuming and operator dependent, we evaluated the X-rays of the patients with computer software and conventional paper-based measurements. The effect of reaming the posterior cortical wall on the inclination of the nail tip to the anterior femoral cortex was detected with measurements on the preoperative and postoperative lateral femoral X-rays by using the CorelDRAW® Graphic Suite X6 software package (Corel, Inc., Ottawa, Ontario, Canada) software. On the same software, X-rays and the posterior reaming amount were also calculated.
Results: The mean age of the patients was 27 years (11–42), while the mean lengthening was 5.9 cm (2–14). The mean consolidation index was 1.05 (0.75–1.62), and the mean follow-up period was 31 months (range, 18–45 months). The mean distance of the osteotomy site to the intercondylar notch of the femur was 81.2 mm (±16.92). The mean displacement of the nail tip position was 15.42 mm (±4.77) on the measurements on the postoperative X-rays after nail insertion compared to the preoperative simulations on the templates. The mean posterior cortex reaming thickness was 3.68 mm (±1.02).
Conclusions: We derived a formula that allows the required amount of optimal posterior cortex reaming to be determined. No impingement-related complications or nail damage were observed.

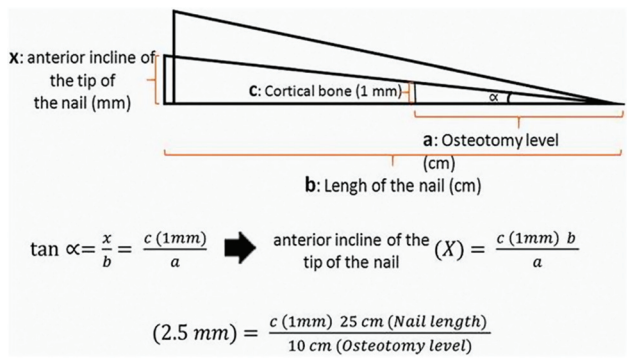

Figure 1:

OS8-64
The use of plastic fasteners for intramedullary nailing

D. Seligson[1]. [1]*Orthopedics, University of Louisville, Louisville, United States*

Bioabsorbable pins and screws can be used to fix fractures. Though less robust in torsion than metal implants, their advantages include bending flexibility and absorption in time.
Problems of tissue reaction are less with current plastic materials.
Bioabsorbables can be used:
1. Around nails for osteosynthesis. 2. Through nails for interlocking and "autodynamization" (avoiding the "Jet Bridge" phenomenon). 3. Beside nails to narrow the effective diameter of the medullary canal.

OS8-65
Buprenorphine/naloxone for maintenance opioid therapy

D. Easley[1], W. Lattice[2]. [1]*Orthopedics, University of Louisville, Louisville, United States,* [2]*Louisville, United States*

Increased opioid use in the United States is a consequence of an aggressive health care policy to lower costs, decrease hospital stays and increase patient satisfaction. The result of this policy – excessive opioid use for injury caused continued overprescribing beginning in hospital and extending to the postoperative period with an increase in pain management clinics and narcotic overprescribing. Legislation aimed at curbing prescription writing of narcotics with stricter enforcement and state registries for narcotic prescription has in the past few years blunted the accelerating growth of narcotics prescriptions. Opioid use however has continued to grow as the cheaper alternative – street Heroin, is readily available. The risks of associated

disease – hepatitis and HIV and death from overdose are growing. Currently, office based opioid substitution therapy with buprenorphine-naloxone is an alternative that allows patients to function productively. The costs of therapy are borne by the patients and some insurers. Abstinence from narcotics while appealing idealistically is a failed strategy for narcotic use disorder.

Poster presentations

P01
Functional analyses after tibial shaft fracture

J. Lackner[1], R. Pätzold[1], I. Kröger[1], A. Brand[1], I. Klöpfer-Krämer[1], P. Augat[1]. [1]*Institut für Biomechanik, Murnau, Germany*

Question: The assessment of fracture healing and prediction of complications or functional restrictions after tibial shaft fracture are important for having corrective intervention on time. X-ray monitoring is the conventional method for assessing fracture healing. However, it is difficult to make an accurate forecast of functional ability by analyzing a static radiograph. Parameters of weight bearing on the affected leg could give useful information for assessing its current functionality as well as further development of the healing process. This study examines, if data of functional analyses could predict and assess the healing process of tibial shaft fractures.
Methods: Five patients with tibial shaft fractures (4 male 30.3 years ±6.4, 1 female 64 years) who were surgically treated with an intramedullary nail participated in the analysis. The current gold-standard for assessing fracture healing by radiograph, the RUST-Score, was analyzed for every test person (12 weeks post-surgery). Additionally, patients` weight bearing on the affected leg was measured during knee-bending on a force plate (AMTI) in % bodyweight (12 weeks post-surgery).
Afterwards, radiograph and weight bearing data was compared to the leg`s functionality one year after surgery, which was recorded by the validated "short musculoskeletal function assessment questionnaire" (SMFA).
Results: The results showed a correlation of –0.98 ($p \leq 0.01$) between weight bearing during knee bending 12 weeks after surgery and the functional outcome one year after surgery. The correlation between the RUST-Score 12 weeks after surgery and the outcome of daily activity one year after surgery was –0.772 ($p \geq 0.05$).
Conclusion: The analyses show a high correlation between weight bearing on the affected leg and a good functional outcome in daily activity. Functional analyses and questionnaires for ability of daily living are mostly not implemented in clinical check-ups. However, the results of this examination show that functional parameters should be considered for assessing the healing process with regard to the functional outcome for daily living.

P02
Evaluation of stress distribution on proximal locking screw position in new designed proximal femoral nail (MNP) using optimized finite element analysis

M.N. Konya[1], O. Verim[1,2]. [1]*Orthopedics and Traumatology, Afyon Kocatepe University, Afyonkarahisar, Turkey,* [2]*Mechanical Engineering, Afyon Kocatepe University, Afyon, Turkey*

Question: Proximal Femoral Nail (PFN) is one of the common used treatment modalities in hip fractures. Placement of the ideal position of the femoral screw is controversial. In this study, our aim is to compare various combination and to determine ideal screw position by using optimized finite element analysis. In this study; we aimed to determine the ideal position with using optimized finite element analysis.

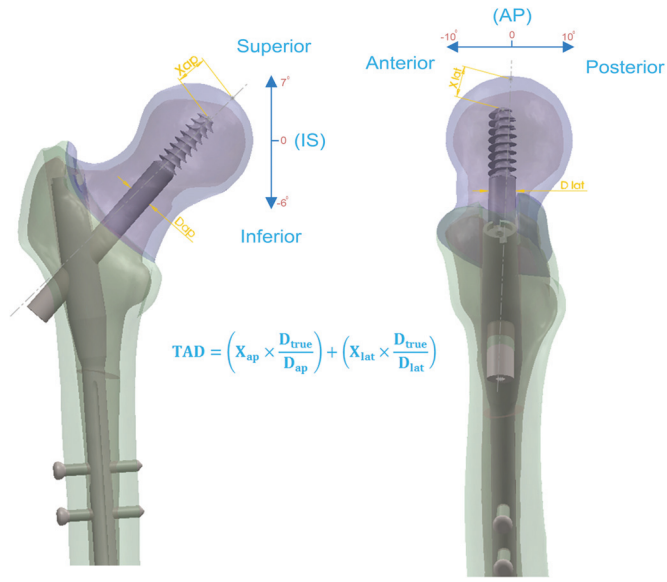

Figure 1:

Methods: Clinical CT scans of a 53-year-old male, admitted to Afyon Kocatepe University, Medical Faculty, Department of Orthopeadics and Traumatology for various reasons, patient's right femur CT images, were converted into a solid model with SolidWorks software (Dassault Systems). The CT scans were collected using a resolution of 512 × 512 pixels with 1 mm between slices. The in-plane resolution varied from 0.625 to 0.977 mm across studies. Bone tissue, heterogeneous because of the different properties of cortical and cancellous structure, shows an anisotropic and nonlinear property. Proximal femur fracture (according to AO classification 31 A1) was simulated and a new design modular PFN prosthesis combination (MNP®) was replaced into femoral channel. The optimal position and Tip-Apex distance (TAD) of proximal screw was analyzed in ANSYS software (Ansys Inc.). Optimization analysis was carried out according to anteriorposterior (AP, from –100 to 100), inferiorsuperior (IS, from –60 to 70) and TAD (from –2 mm to 20 mm) positions of locking screw.

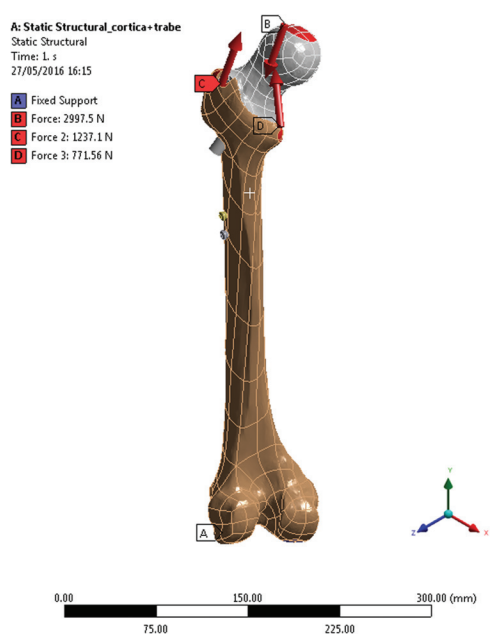

Figure 2:

RSO method is a combination of mathematical expressions and statistical techniques used to analyze the response that is affected by several variables and to optimize the response. For many response surface methods, there is a need to estimate the mathematical forms of the functions between the response and the independent variables in the problems.

Results: In this study, we compared minimum (compression) von Mises stresses on the proximal locking screw according to different positions of proximal locking screw. Initial analysis of system was realized under the surgeon's normal positioning conditions. Maximum and minimum von Mises stresses were found to be 371 MPa, 0.15 MP a respectively and maximum von Mises stress was occurred in the region where lag screw passes through the PFN hole. Maximum stress in cortical and trabecular region was calculated as 64.5 MPa ve 0.5 MPa on the medial calcar region of femur neck. Our results were found safe because the yield stress of cortical and trabecular components were approximately 200 and 1 MPa.

According to compression von Mises stress values occurring on the proximal locking screw, the most suitable position was found at the maximum of the TAD or at the bottom of the femoral neck. The compression stresses occurring on the proximal locking screw are increasing from inferior to superior. Besides, the stresses are decreasing from anterior to middle and are increasing again from middle to posterior.

P03

Femoral insufficiency fractures related to long term bi-phosphonate use and femoral deformity; three cases

M. Akdemir[1], A. Biçen[1], A.C. Turan[1], M.A. Türken[1], A. Arıkan[1], A. Ekin[1]. [1]*Orthopaedics and Traumatology, Izmir University Faculty of Medicine, Izmir, Turkey*

Question: Femoral insufficiency fractures at elderly are rare injuries. İncrease in the usage of biphosponates and aging of the general population we can predict that these kind of fractures will not be as rare as today. We want to discuss our three patient's demographics and treatment results.

Methods: Three female patients at an average age of 70.3 admitted to our hospital with spontaneus femoral fractures. All had prodromal signs of thigh – groin pain. All had a history of long duration of biphosponate use (15-18-30 years). All of them treated open reamerised intramedullary femoral nailing.

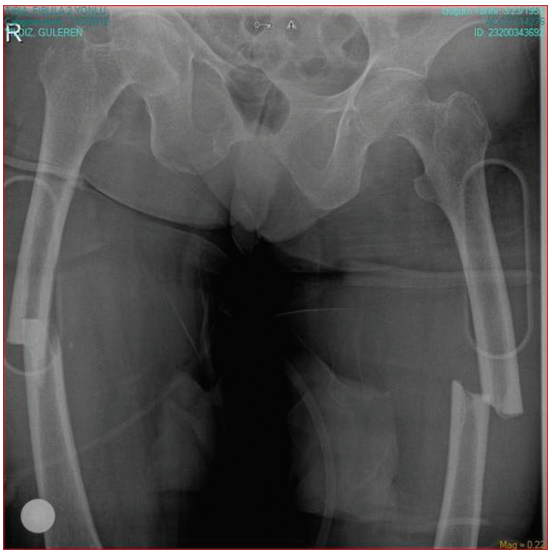

Figure 1:

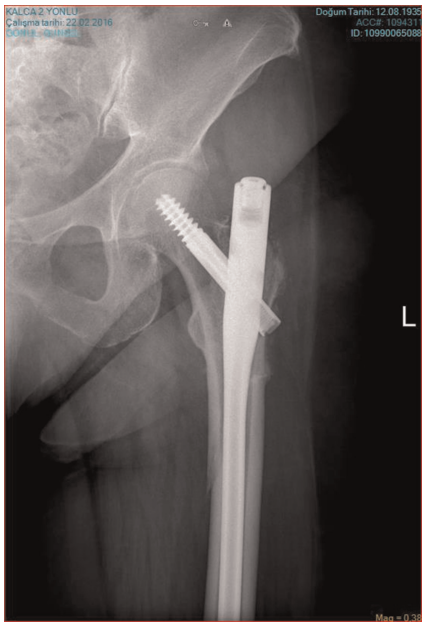

Figure 2:

Results: One patient has bilateral fracture at the shaft. One had proximal femoral fracture. Two of the patients (three femurs) had femoral bowing and one had excessive femoral antevertion. The bilateral femoral fractured patient had also lombar fusion because of spondyloarthrosis. That patient suicide herself 6 months after operation. One patient with shaft fracture developed oligothrophic nonunion two years after the fracture without implant failure and patient refused the reoperation. The fracture with excessive femoral antevertion healed at 3 months but there was no enough callus formation.

Conclusions: Femoral insufficiency fractures by the use of biphosphonate and femoral deformities have a high tendency to nonunion.

P04

Is the tip apex distance a predictor of failure in intertrochanteric hip fractures treated with proximal femoral nail?

K. Kayaokay[1], N. Ozkayin[1], M.C. Sozbilen[1], B. Ozcanyuz[1], J. Mirzazade[1], K. Aktuglu[1]. [1]*Orthopedics, Ege University, Izmir, Turkey*

Aim: Our aim was to evaluate radiographic changes and complications after treatment of intertrochanteric hip fractures with the Proximal Femoral Nail (PFN) and surgical operation performed in postoperative complications.

Methods: The study was done between August 2007 and August 2015. 165 patients with Intertrochanteric fractures were treated with PFN (93 females, 72 males; avg. age 73.15, range 21–104). According to the AO classification, 50 fractures were AI, 79 fractures were AII, 36 fractures were AIII. We used traction table. All patients underwent closed reduction. Patients were followed up: 2 weeks, 1.5 months, 3 months and 6 months. Results were determined radiographically.

Results: According to the results good or acceptable reduction were obtained in all patients. Average Implant tip-apex distance of 32.6 mm (range 8.6–58.4 mm) was measured. Non-unions in two patients (1.2%), cut out in three cases (1.8) were detected. As a radiographic complication, it was observed that the screws come back due to collapse at the fracture line (n = 30). A second operation was done in 5 (3%). Three patients were treated THA, two with hemiartroplasty. These patients had fracture line collapse.

Conclusions: The correct position of the osteosynthesis material and use of an intramedullary nail to obtain a stronger fixation of the proximal part may reduce mechanical complications following the treatment of intertrochanteric hip fractures.

P05

Accuracy of distal long femur nail locking with different techniques

V. Kirdemir[1], î Başal[1], T. Atay[1], Y.B. Baykal[1]. [1]*Orthopedia and Traumatology, Suleyman Demirel University, Isparta, Turkey*

Introduction: Distally locked intramedullary nails (IMN) rely heavily upon the use of the image intensifier and thus exposes the surgeon and operating team to high doses of ionizing radiation [1,2]. The dependence on fluoroscopic imaging for these variations of the free-hand technique makes them undesirable and it is the reason why alternative approaches are welcomed [3]. Numerous innovative techniques have been described such as self-locking nails, navigated nails, and computer-assisted nails [3,4]. All these new technological developments targets to find a new way of a radiation-free method. Because of the risk of cancer that caused by ionizing radiation, some kind of dosimeters also are used during IMN surgeries [5]. We compared four different methods for the distally locked nails in closed femoral shaft fractures. In present study, we evaluated the mean time of distal locking, fluoroscopy times (during distal locking), and drill attempts for distal targeting.

Material and Methods: Of the patients treated by intramedullary nailing in our clinic for closed femoral shaft fractures between 2014 and 2015, the ones who are identical in terms of duration of fracture reduction, guide and nail insertion and proximal locking were included in this study. We have chosen 40 patients who had almost equal times at fracture reduction, insertion of IMN guide and nail, and proximal locking. Four different distal locking systems were applied to each group which consisted of 10 patients with closed femoral shaft fractures. These distal locking techniques were Free-hand technique (Group I), Magnetic-Manual distal locking (Group II), Computer-assisted Electromagnetic distal locking (Group III), and Inside-Out distal locking (Group IV) systems. The study was performed in a single center. All distal locking procedures were performed by a senior resident.

Results: According to the ANOVA test results, distal locking time is similar in Inside-Out and Computer-Assisted techniques. Distal locking times showed no significant difference between two groups (Group IV and III). These two methods were superior to magnetic distal locking and free hand groups (Table 1). The fluoroscopy time was significantly short ($p < 0.05$) in the Group III (2.4 ± 0.84 sec) than group I and II but there were not significant difference between group III (2.4 ± 0.84 sec) and group IV (2.6 ± 0.96 sec).

Table 1
Comparison of four different methods

-	(Group I), Hand-help guide technique	(Group II) Magnetic-Manual Distal Locking	(Group III) Computer Asisted Distal Locking	(Group IV) Inside-Out Distal Locking
Mean Age (years)	34.5(20–46)	31.2(21–8)	34.5(21–47)	36.1(25–48)
Mean time of distal locking	15.1 ± 3.44(min)	7.9 ± 2.8(min)	4.4 ± 1.1(min)	4.2 ± 0.78(min)
Fluoroscopy time	16.8 ± 4.23(sec)	6.8 ± 1.68(sec)	2.4 ± 0.84(sec)	2.6 ± 0.96(sec)
Drill attempt (for 2 holes)	2.9 ± 0.73	2.4 ± 0.51	2.1 ± 0.31	2

Conclusion: Numerous innovative techniques for distally locked IMNs have been described for reducing radiation. Cost and availability plays an important role in the success of targeting devices, or systems, and this must also be considered. The inside-out distal locking and computer-assisted EM targeting technique have come to the forefront than conventional methods. A novel radiation-free targeting system utilizing inside-out guide drilling technology for distal locking, proved to be accurate, fast and reducing operation time and radiation exposure. The main common disadvantage of group II, III, and IV is additional costs.

References

[1] Leloup T., *et al.*, A novel technique for distal locking of intramedullary nail based on two non-constrained fluoroscopic images and navigation. *IEEE Trans Med Imaging*, 2008. 27(9): p. 1202–12.
[2] Leroux T., Khoshbin A., and Nousiainen M.T., Training Distal Locking Screw Insertion Skills to Novice Trainees: A Comparison Between Fluoroscopic- and Electromagnetic-Guided Techniques. *J Orthop Trauma*, 2015. 29(10): p. 441–6.
[3] Whatling G.M. and Nokes L.D., Literature review of current techniques for the insertion of distal screws into intramedullary locking nails. *Injury*, 2006. 37(2): p. 109–19.
[4] Stathopoulos I., *et al.*, Radiation-free distal locking of intramedullary nails: evaluation of a new electromagnetic computer-assisted guidance system. *Injury*, 2013. 44(6): p. 872–5.
[5] Madan S. and Blakeway C., Radiation exposure to surgeon and patient in intramedullary nailing of the lower limb. *Injury*, 2002. 33(8): p. 723–7.

P06

Bundle nailing in proximal fractures of the humerus in the osteoporotic elderly

H. Jansen[1], M. Jordan[1], F. Gilbert[1], R. Meffert[1]. [1]*Unfallchirurgie, Universitätsklinikum Würzburg, Würzburg, Germany*

Background: Despite new angle stable and anatomical preshaped implants we still have problems in osteoporotic proximal humerus fractures. Especially the combination of a subcapital fracture and the additional fracture of the proximal shaft is challenging. Antegrade nailing often shows insufficient stability in the humeral head and can cause problems in cases of a pre-existing omarthrosis. Plate osteosynthesis has also shown its limitations in the osteoporotic bone. Retrograde bundle nailing is a valid- but often forgotten-alternative in these fracture types.

Patients and Methods: We analysed our patients who were operatively treated with retrograde bundle nailing in proximal humerus fractures between 2007 and 2014. Clinical and radiological data collected with a special focus on fracture morpholgy, the incidence of osteoporosis and omarthrosis and complications.

Results: 23 patients (7 males, 16 females) with a mean age of 62.1 (50–80) years were analyzed. There was a subcapital fracture in 5 patients, a fracture of the proximal shaft in 7 patients and a combination of both fractures in 11 patients. 18/23 patients suffered from osteoporosis, 12/23 patients had an omarthrosis. In >90% of the patients had co-morbidities like heart insufficiency or diabetes and 48% were anticoagulated. Mean operation time was 83 (45–136) minutes. Reposition (head-shaft-axis) was 5.8° (0–25) in average. 3 patients (13%) underwent revision surgery due to secondary nail dislocation. Fractures were consolidated after a mean of 5.6 months. After 8.3 (2–37) months the abduction and elevation was 90° (45–180) in average.

Figure 1:

Conclusion: Despite a strong negative preselection of the patients overall satisfactory results could be achieved. Results and complication rates are at least comparably to the alternative treatment options.

P07

Distal radio-ulnar joint inclination affects postoperative functional result after ulnar shortening osteotomy, a retrospective cohort analysis

F. Gilbert[1], R. Meffert[1], M. Jakubietz[1], J. Erdmann[1], R. Jakubietz[1]. [1]*Department of Trauma, Hand, Plastic and Reconstructive Surgery, Julius-Maximilians-University of Würzburg, Würzburg, Germany*

Introduction: Ulna shortening osteotomy is a standard procedure for idiopathic and posttraumatic ulnar impaction syndrome and has shown good clinical results in midterm follow up studies. Reverse oblique distal radio-ulnar joint (DRUJ) inclination is assumed to show inferior postoperative results, as the joint force pressure in the DRUJ may be increased after USO.
Purpose: The purpose of this study was the evaluation and comparison of the postoperative functional result with focus on the DRUJ inclination.
Methods: 45 Patients with ulna shortening osteotomy were included. The minimum follow up was 5 years. The preoperative x-rays were assessed for the DRUJ inclination according to the Tolat classification. Function and pain were assessed using the Disability of the Arm, Shoulder, and Hand score (DASH) measuring the range of motion and the grip strength.
Result: Statistical analysis revealed significant better results in patients with a Tolat type 1 configuration for DASH score, grip strength and range of motion (supination). In the Tolat Type 1 configurated DRUJ mean DASH score was 9 compared to 18 in the Tolat type 2 and 3 group.
Conclusion: These data indicate that patients with parallel aligned distal radio-ulnar joint surfaces show better clinical results than patients with a reverse or a reverse oblique configuration of the DRUJ. Level of Evidence IV

P08

Osteosynthesis in metastatic bone lesions of limbs

V. Protsenko[1], O. Ilnitskyi[1], V. Chorneyi[1]. [1]*Onco-orthopedics, Institute of Traumatology and Orthopedics of NAMS of Ukraine, Kiev, Ukraine*

Introduction: Skeletal metastatic lesions can significantly limit the function of limbs and leads to bone fractures. Osteosynthesis with bone metastases is aimed at restoration of function of the affected limb, improve the quality of life of patients and the possibility of continuing specific treatment.
Materials and methods: During the period from 2009 to 2015 surgical treatment for bone metastases of limb received 64 patients. Tumor localization: femur – 38, shoulder – 20, tibial – 6. Reinforced metalosteosynthesis used in 31 patients, transosseous extrafocal osteosynthesis – 33. The functional outcome of the operated limb was calculated by MSTS scale. Quality of life of patients before and after surgery was carried out on the system EORTC QLQ – C30. The survival rate of the patients was determined by the Kaplan-Meier method.
Results: Postoperative complications were found in 2 (3.1%) patients, recurrent metastatic tumors in 4 (6.2%) patients. Functional results after the operated limb reinforced metal osteosynthesis was 78%, after extrafocal osteosynthesis – 70.2%. The quality of life of patients after osteosynthesis reinforced improved from 40 to 72 points, after extrafocal osteosynthesis with 30 to 66 points. Three-year overall survival: 48.6 ± 0.54%, five-year: 32.4 ± 0.78%.
Conclusions: The use of osteosynthesis in metastatic lesions of the long bones of limbs leads to a better functional outcome of the operated limb, decrease in pain, and improves the quality of life of patients.

P09

The anterior intrapelvic approach to the acetabulum

K. MacKinlay[1], B. Houseman[1], D. Seligson[1]. [1]*Orthopedics, University of Louisville, Louisville, United States*

New tools and new implants make the anterior intrapelvic approach a current technique for anterior column and transverse fractures of the acetabulum. In Our early cases six patients with significant pelvic fractures at the pectinate eminence had a modified Stoppa approach with plate fixation. There were four excellent and two results. Blood loss and operating time were greater than for the more familiar Judet – Letournel approach but the difference was not significant. There was one obturator nerve avulsion. There were no wound complications. The method is promising.

P10

Posterior bridging osteosynthesis for traumatic sacroiliac joint dislocation: a report of seven cases

E. Hoffmann[1]. [1]*Chirurgie Orthopédique, Clinique Sainte Marie, Osny, France*

Objective: To evaluate the long-term clinical and radiographic results in patients treated for 61C3-2 (OTA class) pelvic ring disruption with a posterior bridging sacroiliac fixation.
Design: Retrospective clinical and radiological study.
Setting: University Hospital. Beaujon and Clinique Sainte -Marie
Patients/participants: Between May 2002 and March 2003, seven patients with sacroiliac dislocation were treated with a technique developed for the treatment of pelvic injuries with vertical and horizontal instability.
Intervention: We applied spino-pelvic fixation techniques, using spine instrumentation, to stabilize an SI dislocation. This technique consists of two 5 mm diameter screws inserted into the S1 pedicle and S2 ala. A 5.5 mm joins the 2 sacral screws to two 7 mm screws placed into the posterior iliac crest and secured into the cancellous mass of the posterior ilium. The described technique stabilizes the SI-joint by performing a bridging osteosynthesis instead of the commonly performed iliosacral screw osteosynthesis passing the SI joint. Symphyseal platting is performed to reduce and stabilize the anterior ring if necessary. Main outcome measurements – data were analyzed as follows: pelvic fracture classification; functional outcome; radiographic outcome; Leg length discrepancy; and CT scan aspect of the sacroiliac joint.
Results: Associated pelvic injuries were present in all the patients and include symphysis rupture and acetabular fractures. Four of the seven patients had fractures of the lower extremities. Follow-up was available for all patients at an average of 27 months (range, 32–24 months). Neither septic nor cutaneous complications were reported. No loss of post-op reduction and no fixation failure were observed. The functional results noted at the last examination were satisfactory with a mean Majeed score of 93.
Conclusion: In our opinion, this surgical technique may be indicated in Tile type C1.2 (61C3-2 OTA class) pelvic ring disruption. It obviously reaches its limits in sacral fractures. The technique described provides effective control of vertical displacement while providing a certain degree of horizontal mobility to facilitate reduction and osteosynthesis of anterior lesions. The quality of the fixation allowed early

P11

Outcome of surgical treatment of posterior wall and posterior column fractures of acetabulum

A.M. Teja[1], R.C. Banshiwal[1], M.K. Yadav. [1]*Orthopaedics, Sawai Man Singh Medical College and Hospital, Jaipur, India*

Introduction: 7Acetabulum is a part of major weight bearing joint of lower extremity for that their fractures assume a great clinical importance. Approximately 35% of all acetabular fractures have involvement of posterior wall approximately and 76% of these injuries have additional complex fractures. Displacement of the

fracture fragments in turn leads to rapid breakdown of the cartilage surface, resulting in disabling arthritis of hip joint. Anatomic reduction and stable fixation is the treatment goal in these fractures. Some studies show comparatively good outcome but still recent studies report that 21% to 32% of patients have poor results. Only few studies determined the functional outcome using validated instruments for the complex and simple fractures of the posterior wall separately. Need of present study is to review the effectiveness and complication of the surgical management of these fractures.

Materials and methods: This was a prospective study which included 35 cases of acetabular fractures including 30 males and 5 females. After fulfilling the selection criteria, proper informed consent and screening they were operated for the reconstruction surgery. Clinical and radiological (X-ray-ap & oblique view) follow up at 2 weeks, 4 weeks, 8 weeks, 4 months, 8 months and at 12 month interval was done. At 12 month functional outcome was done using the Modified Merle D′Aubigne and Postel method.

Results: There were 30 males with the mean age 37.7 years and 5 females with the mean age of 52.6 years. The functional outcome at 12 months showed 7 patients (20%) achieved excellent results, 23 patients (65.7%) achieved good results, 2 patients (5.7%) achieved fair results and 3 patients (8.5%) achieved poor results.

Conclusion: Surgical treatment of posterior wall and posterior column acetabular fractures leads to satisfactory functional outcome provided the operation is carried out within first few days following the initial injury and anatomic reduction of the fracture is achieved.

P12

The preferred orientation for screw fixation of the calcaneal tuberosity

S. Gracey[1], D. Seligson[2]. [1]*Podiatric Residency Program, University of Louisville, Louisville, United States,* [2]*Orthopedics, University of Louisville, Louisville, United States*

The traditional open approaches to the calcaneus have a high rates of wound complications. A percutaneous approach with elevation of the posterior subtalar joint, placement of rafting screws and then screw placement from the tuberosity of the calcaneus is an alternative. In this approach the screws from the tuberosity are oriented from the posterior tuberosity anteriorly, superiorly and medially to lie in the sustentaculum and from the postero-medial corner of the tuberosity anteriorly and laterally to lie adjacent to the calcaneo- cuboid joint. These crossing screws follow the geometry of the calcaneus. In five joint depression type cases there were no wound complications and no complaints of prominent or painful implants. Follow-up radiographs showed good healing and stable reductions.

P13

The use of collagen tripeptide, chitosan and hyaluronic acid based hydrogel for posterolateral lumbar spine fusion

S.G. Karaca[1], S. Patir[2]. [1]*Orthopaadic Surgeon, Istanbul, Turkey;* [2]*Biosurgery, Neutech, Frankfurt am Main, Germany*

Study Design: Posterolateral lumbar transverse process fusion was completed using Collagen tripeptide Chitosan and Hyaluronic acid Based Hydrogel.

Objective: To compare the efficacy of cultured bone marrow cells with that of Collagen tripeptide Chitosan and Hyaluronic acid Based Hydrogel as a graft alternative to autologous bone for posterolateral spine fusion.

Methods: Thirty adult rabbits were used. Each underwent single-level, bilateral, posterolateral intertransverse process fusions at L4-L5. The animals were divided into 4 groups, each according to the material implanted:

(1) autologous bone (autograft, n 9)
(2) Collagen tripeptide Chitosan and Hyaluronic acid Based Hydrogel (n 7)
(3) bone marrow cells (1 [1]106 cells/mL, low-marrow-HA, n 7)
(4) bone marrow cells (1 [1] 108 cells/mL, high-marrow-HA, n 7).

Before implantation for groups 3 and 4, fresh bone marrow cells from the iliac crest of each animal were cultured in a standard medium for 2 weeks. For one additional week, the marrow cells were cultured in 10 8M dexamethasone, type I collagen gel, and HA. Animals were euthanized 6 weeks after surgery. Spinal fusions were evaluated by radiograph, manual palpation, and histology.

Results: The fusion rates were 4 of 7 in the autograft group, 7 of 7 in Collagen tripeptide Chitosan and Hyaluronic acid Based Hydrogel group, 0 of 7 in the lowmarrow-HA group, and 5 of 7 in the high-marrow-Ha group. The histology in the Collagen tripeptide Chitosan and Hyaluronic acid Based Hydrogel and high-marrow-HA groups showed that grafted fragments were connected with mature new bone. In the low-marrow-HA group, fibrous tissue was predominant in the grafted fragments Conclusions. This study shows that Collagen tripeptide Chitosan and Hyaluronic acid Based Hydrogel can act as a substitute for autograft or the cultured bone marrow cells in spine fusion. The current formulation may yield improved fusion success and better quality of fusion bone as compared to autograft.

P14

Posterolateral spinal fusion with collagen tripeptide based hydrogel

S.G. Karaca[1], S. Patir[2]. [1]*Orthopaadic Surgeon, Istanbul, Turkey;* [2]*Biosurgery, Neutech İnstitute, Frankfurt, Germany*

Study Design: Lumbar intertransverse process arthrodesis using collagen tripeptide based hydrogel was performed in a previously established rabbit model for posterolateral spinal fusion and compared with fusions achieved using autogenous bone graft.

Objectives: To qualitatively compare different collagen tripeptide based hydrogel dosages and carriers and to determine the efficacy of collagen tripeptide based hydrogel as a bone graft substitute to produce lumbar intertransverse process fusion in a validated rabbit model for posterolateral spinal fusion.

Summary of Background Data: Autogenous bone was considered the most successful bone graft material used for spinal arthrodesis. Problems with its use may occur in 25–30% of patients and prompted the search for an investigation of bone graft substitutes. Collagen tripeptide based hydrogel was used successfully in orthotopic sites to generate bone in animal mandibular and long bone defect models.

Methods: Posterolateral intertransverse process arthrodeses were performed at L5-L6 in 56 rabbits using collagen tripeptide based hydrogel or autogenous bone graft. Rabbits were killed either 5 weeks later to qualitatively compare fusions achieved using collagen tripeptide based hydrogel dosages and carriers or 4 weeks later to compare the efficacy of collagen tripeptide based hydrogel achieving spinal fusion compared with using autogenous bone graft. Inspection, manual palpation, radiography, histology, and biomechanic testing were used to assess the fusion.

Results: All rabbits implanted with collagen tripeptide based hydrogel achieved solid spinal fusion by manual palpation and were fused radiographically, whereas only 42% of the autograft control fusions were solid. More mature fusions with greater trabecular bone formation were shown radiographically and histologically in rabbits implanted with the highdose collagen tripeptide based hydrogel than with the low-dose collagen tripeptide based hydrogel. Fusions achieved using collagen tripeptide delivered in the chitosan carrier were more remodeled and homogeneous compared with using recombinant human bone morphogenetic protein-2 delivered in autograft +/– chitosan carrier. Fusions achieved with collagen tripeptide based hydrogel were biomechanically stronger and stiffer than fusions achieved using autogenous bone graft.

P15
Periprosthetic fractures around the femoral stem: biologic decisions

D. Enchev[1], M. Rashkov[1], A. Baltov[1], M. Markov[1], S. Assiov[1].
[1]*Orthopadic Trauma, Emergency Univercity Hospital N.I.Pirogov, Sofia, Bulgaria*

Objectives: To present clinical results after treatment of periprosthetic femoral fractures using flexible biological decisions.
Material and Methods: For a period of 9 years we have been treating 29 patients with periprosthetic femoral fractures. They were distributed according to AO UCS: IV.3 A1- 2, IV.3 B1- 6, IV.3 B2- 10, IV.3 B3- 4, IV.3 C- 7. ASA physical classification system was used also for the decision. One type A1 fracture was treated non-operatively, one was fixed using Weber technique. All B1 type fractures were stabilized with LCP, cerclages, 3 cases were augmented with massive frozen allografts. The following methods were used for type B2 – 6 noncemented revision implants, 2 cemented revision stems, LCP plate with massive frozen allograft and 1 case was solved with cerclages. For type B3 – 2 noncemented revision stems, 1 cemented revision stem and LCP augmented with allograft. Type C fractures were treated by MIO with LCP but in 2 cases augmentation was performed by intramedullary retrograde fibular allograft.
Results: All patients were followed up. One patient with ASA III died after PE and 1 during the first year from cardiac stroke. From the 27 fractures, 25 (92%) healed uneventfully and returned to pre- injury status with still stable implants. One patient Type C developed non-union and was revised and 1 developed insufficiency fracture bellow the distal end of the plate. There was 1 deep infection which was solved by debridement and local antibiotics. One patient was present with transitory n. peroneus palsy.
Conclusion: Management of periprosthetic femoral fractures indeed warranted further development of surgical techniques. But by flexible biologic decisions which means not only MIO and augmentation with allografts but right balance between early mobility and major surgery we can expect better results.

P16
Should we still arthrodese the knee after retrieving an infected knee prosthesis

P. Reynders-Frederix[1], C. Reynders-Frederix[2]. [1]*Campus Brugmann, University Hospitals Brussels, Brussels, Belgium,* [2]*Campus Saint-Pierre, University Hospitals Brussels, Brussels, Belgium*

The author presents 18 cases of infected knee prosthesis where an attempt was made for knee arthrodesis. In 10 cases multiple reattempts were made to restore function of the knee with intermediate placement of a knee spacer followed by the placement of a revision prosthesis. The other eight patients were arthrodesed immediately after removal of the infected knee prosthesis and protracted antibiotics treatment. Unfortunately in none of our patients achieved a successful arthrodesis. In 12 cases a femoro-tibial nail was used, in three cases a plate and in the other cases an external fixator. In all the cases a mixed flora of predominately staphylococcus aureus, klebsiella and pseudomonas species were found. Amputation was refused in all patients. This functional arthrodesis (failed arthrodesis) was considered useful in 15 patients.
Conclusion: in infected knee prosthesis a functional arthrodesis stabilized by an external support (brace) seems to bring these patients back to a certain functional status which is satisfactory for them in the majority of cases.

P17
Dislocation of knee prosthesis and treatment with Osteobridge(TM) arthrodesis system

M. Akdemir[1], M.A. Türken[1], A. Arıkan[1], A.C. Turan[1], A. Biçen[1], A. Ekin[1].
[1]*Orthopaedics and Traumatology, Izmir University Faculty of Medicine, Izmir, Turkey*

Question: application of knee prosthesis in the presence of arthrosis is increasing. Especially after 1990′s, successful results of knee prosthesis. Although the short term results of knee prosthesis is very good, long term (15–20 years) results are questionable. Our present days (2010′s) are in the time of long term of 1990′s knee prosthesis. İn this study, we want to discuss a long term complication of a knee prosthesis.
Methods: 64 year old female. No history of rheumatoid disease. When she was 18, septic arthritis after open menisectomy developed and a knee arthrodesis was made. 20 years ago, a knee prosthesis was made. She suffered from quadriceps insufficiency and patellar fracture and tendon transfers was made. When she was going down from the stairs, suddenly she felt down and referred to our institution. Before the operation she could barely walk. On the x rays she had knee prosthesis dislocation and also femoral and tibial component osteolysis without gross loosening (Figure 1). She had no open wound and no any neurowascular injury. İn the operation room, we removed the prosthesis and we made a knee arthrodesis with Osteobridge(TM) system and allografts. During the operation, a femoral fissure occurred from the proximal locking, but the construct was stable (Figure 2).

Figure 1:

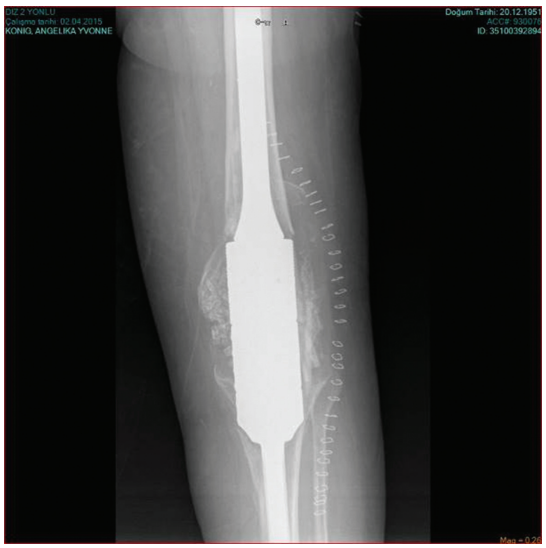

Figure 2:

Results: at the control of 12 months after the operation, the patient could walk alone, give full weight without pain. There was no any infection and loosening of components. The femoral fissure healed uneventfully.
Conclusions: long term complications of the knee prosthesis may be thought as bone and implant related problems. But the soft tissue problems especially ligamentous and muscle problems should be kept in mind. İn the presence of quadriceps insufficiency, knee arthrodesis with Osteobridge system is a mandatory alternative to the revision knee prosthesis.

P18

The analysis of traffic accidents in Uludag university medical faculty emergency service between 2011–2013, Bursa

V.A. Durak[1], M.N. Ural[2], E. Bayraktar[2], M.S. Gürses[3], K. Durak[4], D. Durak[2]. [1]*Department of Emergency medicine, Kırklareli Public Hospitals, Kırklareli, Turkey,* [2]*Department of Forensic Medicine, Uludag University School of Medicine, Bursa, Turkey,* [3]*Tunceli Regional Office of Council of Forensic Medicine, Forensic Medicine Department, Tunceli, Turkey,* [4]*Department of Orthopaedic Surgery, Uludag University School of Medicine, Bursa, Turkey*

Objectives: Traffic accidents seem to be one of the leading problems that cause injuries and deaths in lower-income and developing countries. According to the WHO (World Health Organization) data, traffic accidents take part in the first place of factors that cause death. Also it is an important problem of health for our country. In our study we aimed to identify the demographic values of accident victims, characteristics of accident types, the factors that affect the accidents and discuss them together.
Materials and Methods: During the period between 1 January 2011 and 31 December 2013; 248.011 patient records were reviewed and 2604 (1.05%) victims of RTA′s were evaluated. The trauma files were examined for patients' age, gender, type of trauma, physical examination reports, laboratory and radiological analysis reports, Glasgow Coma Scale (GCS) score, time of trauma, transport type to hospital, presence of alcohol and blood alcohol concentration, localisation of injuries, and outcomes.
Results: Of the 2604 patients; 762 (29.3%) of them were female and 1842 (70.7%) of them were male. There was a significant decrease in motor vehicle and pedestrian accidents during the year 2013 ($p < 0.001$). Traffic accidents seemed to happen between the hours 00:00–06:00 (1.4%) and trauma according to the accidents happened most frequently in motor vehicle accidents in 1865 (71.6%) cases. 153 patients had alcohol in their blood samples and these patients were found to have accidents between 00:00 and 06:00.
Conclusions: In our study; we identified a decrease in traffic accidents in our region by the data. Also we concluded that the injury rates could decrease with the controls during late night time and increase of security measures.

P19

Evaluation of efficacy and complications of chevron osteotomy with k-wire fixation for Hallux valgus correction

M. Baig[1]. [1]*University Hospital Kerry, Tralee, Ireland*

Introduction: Hallux valgus is one of the most common forefoot deformity worldwide with incidence of 23% to 35%. Its aetiology includes both the hereditary factors such as metatarsus primus Varus and acquired as splayed foot secondary to weak intrinsic or ill fitted shoes. Women are affected more than men. Clinically three most common symptoms are Painful bunion, transfer metatarsalgia and associated hammer or claw toes secondary to valgus deviation of big toe.
Aims: The aim of this study was to evaluate our practice of chevron osteotomy with k-wire fixation for hallux values correction. We wanted to evaluate the clinical and radiological efficacy of chevron osteotomy and then wanted to look for any complications with our method of fixation (k-wire).
Method: We did a prospective study and following them up for 1 year who underwent chevron osteotomy for hallux valgus correction from June 2014 to Jan 2016. We included patients younger than 75, we collected the demographic data along with clinical and radiologic data. Clinically assessment was done by AOFAS hallux valgus score and radiologic assessment was done by pre-op and post-op MTP and IM angle.
Results: The range of patients age is from 28 to 73 years. Out of 20 patients 19 were female and 1 male patient. The AOFAS mean score was 50.70 pre-op and at 1 year post- op follow up the mean score was 82.4. The Metatarsophalangeal angle changed from mean of 25.60 pre-op to 13.85 at 1 year post-op follow up. There were 6 complications out of 20 cases including 4 k-wire complications.
Conclusion: The results of the study do show that chevron osteotomy for the hallux values correction is a reliable and time tested procedure both clinically and radiologically. There are many methods of fixation after the osteotomy, and in our centre we used the k-wire fixation which as the study shows has high complication rate. So we need to observe the difference between the k-wire and other kinds of chevron osteotomy fixation methods and refine or change our method of fixation.

Figure 1:

Figure 2:

P20
Implant removal: patients expectations and surgeons concerns

A.L. Drissner[1], T. Völler[1], T. Mittlmeier[1], R. Rotter[1], A. Wichelhaus[1], P. Gierer[1]. [1]*Trauma-, Hand- & Reconstructive Surgery, University of Rostock, Rostock, Germany*

Question: Systematic removal of orthopaedic implants remains a controversially discussed topic. While retained implants may cause stress shielding and mechanical irritation, implant removal may lead to avoidable complications. Moreover, patient's expectations concerning the potential benefits differ from surgeon's experience. The aim of this prospective investigation was to determine whether patient's expectations are realistic or not.
Methods: In a prospective case series all patients with scheduled implant removals in our department were recorded since January 2015. Implant removals due to infect, pseudarthrosis or arthroplasty were excluded. A questionnaire according the patients expectations was handed out before the surgical intervention. Additionally, the surgeon was asked about his opinion to the surgical intervention of removing the implant. 3 months later the patients were asked again in as much their expectations had been fulfilled. Intraoperative technical problems were recorded.
Results: Until now 160 implants (112 patients) were recorded. The follow up questionnaire was completed in 151 cases. Mean age of the patients at the time of operation was 41.1 years (18–78). Pain level according to the visual analogue scale decreased from 4.0 (±2.7) to 2.4 (±2.2) three months after implant removal. 89.4% of the patients expected a positive result of the operation, but only 42.5% of the surgeons did so. Three months later 70% of the patients felt satisfied with their decision to leave the implant removed.
Conclusion: Despite the fact that we are presenting preliminary data, out of an on-going survey, it is interesting that 70% of the patients were satisfied according their expectations concerning the operation. Summing up, scheduled implant removal seems to be more reasonable than its reputation. Nevertheless, implant specific complications have to be taken in account.

P21
Three-dimensional polymer coated 45S5-type bioactive glass scaffolds seeded with human mesenchymal stem cells show bone formation in-vivo

F. Westhauser[1], M. Prokscha[1], C. Weis[2], W. Li[3], U. Kneser[4], H.-U. Kauczor[1], G. Schmidmaier[1], A. R. Boccaccini[3], A. Moghaddam[1]. [1]*Trauma and Reconstructive Surgery, Heidelberg University Hospital, Center of Orthopedics, Traumatology, and Spinal Cord Injury, Heidelberg, Germany,* [2]*Clinic of Diagnostic and Interventional Radiology (DIR), Heidelberg University Hospital, Heidelberg, Germany,* [3]*University of Erlangen-Nuremberg, Institute of Biomaterials, Erlangen, Germany,* [4]*BG-Unfallklinik Ludwigshafen, Klinik für Hand-, Plastische- und Rekonstruktive Chirurgie, Ludwigshafen, Germany*

Objective: In orthopedic surgery, the treatment of bone defects is a major challenge. Autologous bone grafting is the gold standard in therapy; however the amount of autologous bone is limited. Therefore there is an increased need for bone substitutes. Standard materials such as beta-Tricalciumphosphate (ß-TCP) are limited in their osteostimulative capabilities. Solid 45S5-type bioactive glasses (BG) are a promising alternative to established substitutes. However, the three-dimensional (3D) structure of bone substitutes is crucial for bone ingrowth and formation. 3D-structured porous BG scaffolds can potentially combine the advantages of the material itself with structural characteristics supporting bone formation. Therefore, we evaluated the osteoinductive properties of different polymer coated 3D-45S5 BG-scaffolds seeded with human mesenchymal stem cells (hMSC) in-vivo.
Materials and Methods: BG scaffolds coated with gelatin (Group A), cross-linked gelatin (Group B), and poly(3-hydroxybutyrate-co-3-hydroxyvalerate) (Group C) were seeded with hMSC prior to subcutaneous implantation into severe combined immunodeficiency mice. Newly formed bone was evaluated with histomorphometry and micro-computed tomography (mCT).
Results: Bone formation was detectable in all groups. Gelatin-coated scaffolds showed the best results in terms of the amount of newly built bone. In mCT, bone formation in A showed a planar character with bone islands connected to each other. In B and C, bone formation had a more singular character without signs of interconnectivity.
Conclusions: 3D 45S5 BG scaffolds are capable of inducing bone formation under standard conditions. Gelatin-coating showed the best osteoinductive potential compared to the other coatings investigated, thus gelatin coated 3D-45S5 BG are an attractive scaffold type warranting further evaluation in further studies. A direct comparison to established materials such as ß-TCP can help to assess the osteoinductive potential directly.

P22
Treatment of bone and soft tissue infections and sepsis due to war injuries including polytrauma

M. Akdemir[1], A. Erbay[2], A.C. Turan[1], M.A. Türken[1], A. Arıkan[1], A. Biçen[1], A. Ekin[1]. [1]*Orthopaedics and Traumatology, Izmir University Faculty of Medicine, Izmir, Turkey,* [2]*Infectious Diseases and Microbiology, Izmir University Faculty of Medicine, Izmir, Turkey*

Question: Infectious complications of war injuries are one of the most influential complications both for mortality and morbidity. These injuries should be considered as systemic injuries because of mechanism of injury. We reviewed 8 cases of septic combat related patients and multiple trauma.

Methods: All of these eight patient's primary treatment was made at another country and referred to our institution at least five days later (5–21 days). All of them were combat related injuries during Libyan war and their primary care were taken at Tunisian hospitals. They were transported by air to our institution. All of the patients were at sepsis and later blood cultures were positive except one. After first aid, we made serial debridements, culture sample, and fix the bone with external fixation. We gave the antibiotics according to the pathogen. We finish the antibiotic treatment after clinical wound healing and negative cultures. We made reconstructive procedures after control of the infection.
Results: All of the patients had missile or gunshot injury, they were at septic shock and additional fractures and soft tissue injuries as blast injury, referred as polytraumatic injures. Only one patient had single pathogen. The others had multiple bacterial agents from different sites with high antibiotic resistance. Seven patients managed with sepsis but one patient with head and splenic trauma died of septic multisystem failure.
Conclusions: combat injuries complicated with sepsis and polytrauma are challenging. İn our series these patient were referred to our institution at the immunosuppression phase of polytrauma. Also their primary care were taken at another country and they had poly-microbial highly resistant infections. After first primary care, aggressive serial debridements and very effective intensive care unit are mandatory. Especially high missile injuries, additional blast related injuries should not be underestimated.

Figure 1:

P23

Comparison of the reliability of three methods for the assessment of the lower limb length: EOS with new micro-dose protocol vs. long-standing radiograph vs. ct scanogram

B. Abay[1], M.F. Erol[2], M. Kucukkaya[1]. [1]*Orthopedics and Traumatology, Istanbul Bilim University, Istanbul, Turkey,* [2]*Orthopedics and Traumatology, Namik Kemal University, Tekirdag, Turkey*

Question: As the technology for the acute correction of the adult deformities with the new internal fixation devices like the intramedullary lengthening nails advances, the need for reliable imaging modalities for the measurement of lower limb length increases for preoperative planning and assessment of the appropriate treatment. In this study, we compared the inter-rater and intra-rater reliability of EOS with new micro-dose protocol, long-standing radiograph (LSR) and computed tomography (CT) scanograms for the assessment of the lower limb length.
Methods: 14 lower limbs of 7 patients (7 men; mean age, 31 years; range, 25–46 years) were assessed with three methods of radiological imaging modalities, EOS with new micro-dose protocol, CT scanogram and LSR with using a small radiopaque sphere. The standardized measurements of bone lengths (femur and tibia) and total lengths of the lower limb were made by the three investigators on a 2 separate occasions at a minimum of 4 weeks apart. Descriptive statistics of three modalities were calculated.
Results: Inter-rater reliability, quantified with Intraclass Correlation Coefficients, showed excellent (>0.90) agreement for LSR, CT scanogram and EOS. Intraclass correlation coefficients (ICC) showed excellent (>0.90, $p < 0.001$) intra-observer reliability for the measurements of the lengths of the lower limb, femur and tibia with EOS, 0.99, 0.98 and 0.99 respectively, with LSR 0.97, 0.98 and 0.99 respectively, and with CT scanograms 0.99, 0.98 and 0.99 respectively.
Conclusions: The reliability of the measurements of the LSR is similar to the measurements with the CT scanogram and EOS with new microdose protocol provided the appropriate technique of the calibration is done. Single -exposure LSR with using a small radiopaque sphere for the calibration might be better choice of imaging modality for the assessment and preoperative planning of the lower limb deformities.

P24

Impact of medication use on fracture nonunion in human bones: analysis of a payer database of ~90.1 million patients

R.G. Steen[1], Z. Xiong[1], T. Einhorn[1], J.T. Watson[1], M.J. Prayson[1], G.J.D. Rocca[1], T. McKinley[1], S. Mehta[1], Z. Wang[1], Robert D. Zura[1]. [1]*Louisiana State University Health Science Center, New Orleans, United States*

Introduction: Biologic risk factors have a significant impact on fracture healing, but most factors cannot be mitigated. Patient medications are unusual in that they have a significant impact on fracture healing and can potentially be adjusted by a physician after fracture. We hypothesize that risk associated with medications accrues to chronic use prior to fracture.
Methods: Patient-level health claims for medical and drug expenses were compiled for ~90.1 million patients. Study inclusion was limited to patients with a coded bone fracture in calendar year 2011, with continuous enrollment for 1 month prior and 12 months after fracture, to allow time to assess chronic medication use. Chronic medication use was defined as medication use ≥30 days prior to fracture with continued use after fracture. The final database contained 268,784 fractures, with demographic descriptors, treatment procedures per Current Procedural Terminology (CPT) codes, co-morbidities per International Statistical Classification of Diseases and Related Health Problems (ICD-9) codes, and drug prescriptions per National Drug Code Directory (Red Book) codes. Logistic regression was used to calculate odds ratios for nonunion associated with chronic use of medications. This study was exempted from ethical approval by the Institutional Review Board of Duke University Medical Center because patient data were completely de-identified.
Results: A total of 43,727 fractures (16.3% of 268,784 fractures) affected patients using chronic pain medications. The nonunion rate among chronic pain medication users was 7.35%, while the nonunion rate among non-chronic pain medication users was 4.04% ($p < 0.001$). The nonunion rate in non-chronic pain medication users was equivalent to the overall rate of nonunion in an epidemiologic study of fracture patients [1]. Chronic pain medication users were significantly more prone ($p < 0.001$) to nonunion at every age and in both genders, and chronic pain medication use increased the rate of non-union rate associated with multiple fractures, past or current

smoking, or diagnosed alcoholism. Chronic use of opioid agonists, opioid partial agonists, salicylates, prescription NSAIDs, unclassified NSAIDs, benzodiazepine, and miscellaneous anticonvulsants significantly increased risk of non-union in 18 bones (all, multivariate $p < 0.001$). Nonunion risk was also significantly increased by chronic use of antibiotics (cephalosporin, erythromycin/ macrolides, penicillin, miscellaneous), cardiac medications (antiplatelet agents, ACE inhibitors, beta blockers, calcium channel blockers, unclassified medications), and anticoagulants (all, multivariate $p < 0.001$). Conversely, non-chronic medication use, even of opioid analgesics, prescription NSAIDs, and anticonvulsants, did not increase nonunion risk. Oral contraceptive use was protective from nonunion ($p < 0.001$).
Discussion: Physicians concerned with fracture nonunion risk should consider counseling patients to avoid chronic medications such as opioids, prescription NSAIDs, anticonvulsants, some cardiac medications, and anticoagulants.
Significance: Our results suggest that chronic medication use is a significant and substantial risk factor for fracture nonunion. It is critical that trauma surgeons be aware of the nonunion risk created by medication use because trauma patients may represent a population enriched for nonunion risk factors. In fact, warning signs of pain medication abuse may ultimately be risk factors for fracture nonunion.
Disclosures: All authors have worked for Bioventus, either as consultants or employees.

P25
Assessment of low-intensity pulsed ultrasound on fracture healing as used in a level-1 trauma centre

A. Welch-Phillips[1], C. Kennedy[1], J. Harty[1], M. Athar[1]. [1]*Trauma and Orthopaedics, Cork University Hospital, Cork, Ireland*

Background and Literature Review: Many fracture patients experience delays in fracture union despite intensive care and surgical intervention. Low intensity pulsed ultrasound has been proposed as a modality which assists fracture healing by reducing healing times and improving boney callus formation. EXOGEN is a new LIPUS device which is poorly studied and requires standardization in terms of efficacy.
Aims and Objectives: To determine the rates of union and non-union in patients who were prescribed EXOGEN therapy for the treatment of a complicated fracture.

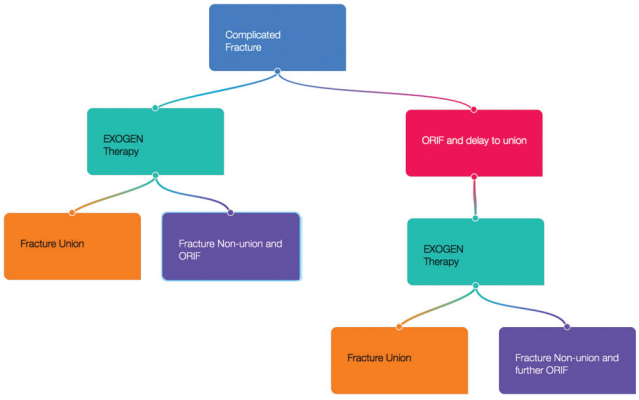

Figure 1: The Patient cohort is divided into 4 basic groups. The first arm of the cohort had EXOGEN therapy after a fracture in order to circumvent the need for surgery. Of this group there are those that experienced fracture union and those that had non-union requiring ORIF. In the second arm of this cohort we have those patients who required immediate ORIF and experienced subsequent delay in fracture union despite surgical intervention. In this group we have those that experienced fracture union following EXOGEN therapy, and those that required revision surgery despite EXOGEN therapy.

Methods: This study is a retrospective databases analysis conducted at a level-1 trauma center. Patients prescribed EXOGEN therapy from 2011–2013 were identified. These patients were then categorized in to fresh fractures or post-operative fractures. The rates of union and non-union were determined for fresh and old fractures with the use of patient records and imagining. The average healing times for fractures that achieved union were also determined.
Results: Based on this analysis we have found a 51.6% union rate in the circumstance of fresh fractures and 73.5% union rate in the circumstance of post-operative fractures. We have also found that the average healing time of EXOGEN assisted fresh fractures and old fractures was 141±87 and 190±96 days, respectively.
Discussion and Conclusion: This analysis establishes union rates and average healing times for EXOGEN as a LIPUS modality. The union rates produced by this analysis are not as impressive as other studies however this may relate to the various fracture sites studied here. Additional, analysis needs to be conducted, comparing these values to controls. This additional investigation would determine if union rates are superior in EXOGEN assisted fractures.

P26
The effectiveness of transforaminal versus caudal routes for epidural steroid injections in managing lumbosacral radicular pain: a systematic review and meta-analysis

J. Liu[1], H. Zhou[1], L. Lu[1], S. Feng[1]. [1]*Department of Orthopedics, Tianjin Medical University General Hospital, Tianjin, China*

Background: Epidural steroid injection (ESI) is one of the most commonly used treatments for radiculopathy. Previous studies have described the effectiveness of ESI in the management of radiculopathy. However, controversy exists regarding the route that is most beneficial and effective with respect to the administration of epidural steroids, as both transforaminal and caudal routes are commonly used.
Objective: This analysis reviewed studies comparing the effectiveness of transforaminal (TF) epidural steroid injections with that of caudal (C) epidural steroid injections in the treatment of radiculopathy as a means of providing pain relief and improving functionality. This meta-analysis was performed to guide clinical decision making.
Study Design: This study was a systematic review of comparative studies.
Methods: A systematic literature search was performed using the PubMed, EMBASE, and Cochrane Library databases for trials written in English. The randomized trials and observational studies that met our inclusion criteria were subsequently included. Two reviewers respectively extracted data and estimated the risk of bias. All statistical analyses were performed using Review Manager 5.3.
Results: Six prospective and 2 retrospective studies involving 664 patients were included. Statistical analysis was performed utilizing only the 6 prospective studies. Although slight pain and functional improvements were noted in the transforaminal epidural steroid injections groups compared with the caudal epidural steroid injections groups, these improvements were neither clinically nor statistically significant.
Limitations: The limitations of this meta-analysis resulted primarily from the weaknesses of the comparative studies and the relative paucity of patients included in each study.
Conclusions: Both the transforaminal and caudal approaches are effective in reducing pain and improving functional scores, and they demonstrated similar efficacies in the management of lumbosacral radicular pain.

P27
Alcohol involvement in traumatic fatal injuries

V. A. Durak[1], M. Kocaman[2], T. Aydogan[2], D. Durak[2]. [1]*Kırklareli State Hospital, Kırklareli, Turkey,* [2]*Forensic Medicine, Uludag University, Bursa, Turkey*

Background: Alcohol consumption is a major risk factor of avoidable diseases and injuries in many countries, besides that the influence of

ethanol in fatal injuries cohort is lacking. The aim of this study was to investigate the correlation between alcohol and features of the fatal injuries in South Marmara region, Turkey, in the period of 2013 to 2015.

Method: Historical cohort of 4535 autopsy cases performed at Bursa Morgue Department of Forensic Medicine Institute between January 1, 2013 and December 31, 2015. We detected alcohol in 490 cases, 175 of those were excluded from the study because of non-traumatic reason of death and decomposition. Age, gender, Blood Alcohol Concentration (BAC), disposition and the mechanism of death were investigated. BAC was divided into 5 groups by 100 mg/dL intervals.

Results: Age of included cases were ranging between 14 and 83 years. Only 20 of all cases were female (6.3%), 295 were male (93.7%). Alcohol related traumatic deaths were seen most frequently between the ages 40–49 (23.8%) and in summer. Traffic accidents (26%) were the most common cause of alcohol related traumatic deaths. The differences was statistically significant in the mechanisms of death between the age groups (p

Conclusion: Alcohol involved fatal injuries are 6.9% of all deaths. Injury prevention strategies and education directed at reducing alcohol involvement in injuries can contribute to the reduction of alcohol related traumatic deaths.

P28
Is Fetuin-A serum concentration a predictor of long-term outcome after proximal femur fracture in osteoporotic patients?

P. Herlyn[1], C. Steffen[1], N. Cornelius[1], T. Mittlmeier[1], D.-C. Fischer[2]. [1]*Universitätsmedizin Rostock, Abteilung für Unfall-, Hand- und Wiederherstellungschirurgie, Rostock, Germany,* [2]*Universitätsmedizin, Kinder- und Jugendklinik, Rostock, Germany*

Question: Fractures of the proximal femur are associated with high postoperative mortality and subsequently reduced physical function. Fetuin-A is a multifunctional protein that acts as an inhibitor of ectopic calcification while favoring mineralization of bone. Epidemiological studies in elderly women showed an association between Fetuin-A serum levels and BMD. In this retrospective follow-up study we investigated the relation between Fetuin-A serum concentrations and long-term outcome after fractures of the proximal femur.

Methods: Recently, we analysed bone microarchitecture and kinetics of Fetuin-A at time of fracture (t0) and during postoperative recovery (t1 and t2) in osteoporotic patients presenting with low energy fracture of the proximal femur [J Clin Densitom 2014]. Approximately 2 years later we re-examined this patient cohort with respect to Fetuin-A serum levels, anthropometric and clinical characteristics, i.e. Harris Hip Score and Merle d'Aubigné and Postel Score, Timed up and go test, Chair rising test, Tandem-stand test and handgrip strength were determined. A trauma centered History of disease including fractures and falls was derived from chart review and interview. A summary score ("overall outcome") was developed and a Principal Components Analysis enabled us to summarize physical performance as one variable.

Results and Conclusion: From the patients enrolled previously, 58 (15m/43f; (78.8±11.3 years) were still alive and 46 (14m/32f; 80.2± 11.7 years) consented to participate. Both of the newly defined variables, i.e. overall outcome and physical performance were positively associated with perioperative serum concentrations of Fetuin-A (t2: $r = 0.55$ and $r = 0.54$ respectively, each $p < 0.01$). Multiple linear regression analysis revealed Fetuin-A serum concentration at t1 and t2 as independent predictors of physical performance. Thus we conclude that perioperative Fetuin-A serum concentrations may serve as predictor of functional outcome in patients with low energy fractures of the proximal femur.

P29
MMP-8 and MMP-9 serum levels as possible early markers for remission after traumatic spinal cord injury

R. Heller[1], V. Daniel[1], T. Swing[1], M. Akbar[1], H. J. Gerner[1], B. Biglari[2], A. Moghaddam-Alvandi[1]. [1]*Universitätsklinikum Heidelberg, Heidelberg, Germany,* [2]*BG Unfallklinik Ludwigshafen, Ludwigshafen, Germany*

Matrix metalloproteins play a crucial role in the secondary phase of injury after traumatic spinal cord injury (SCI) and therefore have a large impact on neurological remission. We investigated serum cytokine levels as predictive markers. Between 2010 and 2015, datasets from 115 patients (33 female, 82 male) after traumatic SCI were recorded at the BG Trauma Centre Ludwigshafen. We examined the serum levels of MMP-2, MMP-8, MMP-9, MMP-10 and MMP-12 over a 12-week period, i.e., at admission (on average less than two hours after trauma) and 4, 9, 12 hours, 1 and 3 days and 1, 2, 4, 8, 12 weeks after trauma. Following the same match-pair procedure as in our previous studies, we selected 10 patients with SCI and neurological remission (Group 1) and 10 patients with an initial American Spinal Injury Association (ASIA) A grade and no neurological remission (Group 0). Ten patients with an isolated vertebral fracture without neurological deficits served as a control group (Group C). Our analysis was performed using a Luminex Performance Human High Sensitivity Cytokine Panel. SCI was classified using the ASIA Impairment Scale (AIS) at time of admission and after 12 weeks. Multivariate logistic regression models adjusting for clinically relevant covariates were used to examine the predictive value of MMP with respect to neurological remission vs. no neurological remission. MMP-8 and MMP-9 provided significantly different values for neurological remission and no neurological remission. The favoured predictive model allows to differentiate between neurological remission and no neurological remission in 97% of cases. The results indicate that further studies with an enlarged collective might be warranted in order to investigate current monitoring, prognostic and tracking techniques as well as scoring systems.

Invited lectures

IL03
Proximal femur fractures

A. Steindl[1]. [1]*Universitätsklinikum St. Pölten, St. Pölten, Austria*

Proximal femur fractures are seen globally and are a serious concern at the individual and population level. All populations experience hip fractures but numbers vary with race, gender, and age. Age is the most dominant factor in hip fracture injuries, with most cases occurring in people over 75. Women suffer three times as many hip fractures as men. In a lifetime, men have an estimated 6% risk whereas postmenopausal women have an estimated 14% risk of suffering a hip fracture. By 2050 it is estimated that there will be 6 million cases of hip fractures worldwide. The average age for suffering a hip fracture is 77 years old for women and 72 years old for men. The rate of one year mortality is seen from 12–37% – up to a third will die within a year of the hip fracture! One study found that in 2011, femur neck fractures were among the most expensive conditions seen in US hospitals.

These facts require from science and medical care continuous improvement of methods and techniques in fracture treatment in this cases. The first purpose has to prevent the incurrence of fracture – a very important disorder concerning this type of fracture is the treatment of osteoporosis of elderly person.

There are developed many different methods to treat this fracture type surgically – depending on fracture localization and fracture type.

Some of these techniques should be shown in this presentation to initialize this lecture.

IL04

Femur shaft and supracondylar fractures

D. Seligson[1]. [1]*University of Louisville, Orthopedics, Louisville, United States*

With the resurgence of operative fracture care during my career, femur nailing and plate fixation were standard methods for femur shaft and supracondylar fractures respectively. Gerhard Küntscher's cloverleaf nail evolved to a closed section interlocking nail now a worldwide standard. The osteotomy plate for supracondylar fractures was not only difficult to implant but also had a high failure rate. At the meetings of our Küntscher Society the concept of a nail driven from the knee had its debut and achieved wide acceptance not only for the elderly with simple and not so simple supracondylar fractures, but also for situations where nailing from the knee is easier. Today with improved implants we have improved results particularly in patients with good bone with the use of modern locked plating techniques. Tomorrow solutions will present for the biological problems of fracture healing with high energy tissue damage and the mechanical problems when too narrow nails fail to restore the normal flow of force through bone. Materials will change so that implants will disappear in time. The future will bring as many changes as we have experienced in our careers.

IL05

Proximal humerus fractures

M. Kloub[1]. [1]*Traumacenter Ceske Budejovice, Traumatology Department, Ceske Budejovice, Czech Republic*

Fractures of proximal part and shaft of the humerus involve very different types of fractures with specific complications. Current spectrum of angular stable plates and nails allows use of the optimal implant in each fracture type. In proximal humerus patients demands differ according to the age and activity of the patient – for younger patients reconstruction with stable osteosynthesis remains the gold standard of the treatment for displaced fractures, in elderly early return to pre-injury quality of life is preferred, especially in fractures with high risk of head necrosis development. For diaphyseal fractures different techniques could be used, from mini-invasive nailing or plating to ORIF.

Preferred strategy of the treatment of these heterogenous group of fractures will be presented with emphasis on key-points in each area.

IL06

Distal humerus fractures

N. Spranger[1]. [1]*Unfallkrankenhaus Berlin, Klinik für Orthopädie und Unfallchirurgie, Berlin, Germany*

17–30% of all injuries of the elbow are located at the distal humerus. Despite to other fractures of the upper Extremity we face here up to 45% accompanied injuries, like neurological palsy or vascular complications or open fractures.

The treatment of these fractures depends on the age, fracture pattern, soft tissue damage and the co-morbidity of the patients, and shows a huge variety from conservative treatment up to primary joint replacement.

In this talk there will presented an overview about the keystones in diagnostics and different treatment options depending on the different kinds of these injuries.

Additionally the problems and pitfalls in treating children, high-energy accidents and fractures of the elderly will be outlined. Besides recent literature to this topic, the author will show different cases with partly severe complications.

The aim of this presentation will be to provide the audience a quick summery in treating options of distal humeral fractures and point out the possible complications and proposal to avoid them, as well to show possible solutions to tricky cases.

IL09

Overview lecture: ankle, pilon and distal lower leg fractures

W. Friedl[1]. [1]*Department for Trauma and Reconstructive Surgery, Klinikum Aschaffenburg, Aschaffenburg, Germany*

Clinical Problem: Pilon fractures and distal metaphyseal fractures of the tibia are associated with a high rate of soft tissue and bone healing problems. In type C fractures the stabilisation of the articular dislocation and the internal fixation of the pilon to the tibia shaft is difficult and the use of plates associated with a high rate of severe complications including osteomyelitis. The External fixation in type C fractures is often not possible, not stable and has a risk of fracture site infection and in all types not favourable for the functional therapy and patient comfort. We started to use the XS and XS nail as minimal invasive procedure for the management of these fractures in July 2000 first for the fibula and since for the fibula and pilon itself. Extended metaphyseal comminution are contraindication for the XS nail. Because of soft tissue problems and higher loading capacity of intramedullary implants the XS Nail was also used for ankle fracture osteosynthesis

Material and Methods: the XS nail is a 4.5 mm and the XXS a 3.5 mm straight nail witch is locked by threaded wires witch are placed with an aiming device and allows also dynamic fracture site compression with a set screw. Dislocated articular pilon fracture are reduced with limited incisions and fixed with cannulated screws. The Fibula is fixed percutaneusly and after distal locking with traction of the aiming device also tibia length and axis can be restored and fixed with the proximal locking. The Tibia is than fixed with one nail introduced from the medial malleolus and if necessary a second from proximal medial to distal lateral so that stable fixation is obtained. From July 2000 to July 2003 26 pilon fractures where treated. The mean age was 54 years (range 25–92). In all cases except one referred after 4 weeks the fibula and joint dislocations where stabilised primarily. The tibia XS nail osteosynthesis or minimal invasive plate fixation was performed after 5–8 days except two fixed primarily. Up to now 13 patients (7 type C and 6 type A) could be re-examined more than 6 and 12 months after surgery. The results were classified according to the Ovadia Score. In a second study: from 05/2000 to 03/2002 214 ankle fractures were stabilised with a XS or XXS nail (locked straight nail of 4.5 and 3.5 mm). The mean age was 51 years, 59% were woman. 35% were Weber B and 25% type C fractures. The re-examination after 6 months could be performed in 91 Patients and was evaluated according to the Ovadia score (clinical and radiological).

Results: All articular fractures and fibula fractures healed without problems but in 3 metaphyseal fractures delayed union (including one case of bone and soft tissue defect) required bone grafting. In the same tree patients retrograde suralis flaps had to be performed. In no case osteomyelitis occurred. In one case compartment syndrome required surgical decompression. According to the Ovadia Score after 6 months 31% of the patients had good, 38% had satisfactory but another 31% unsatisfactory results but after one year the results were very good or good in the subjective criteria in 69% of the patients and 61% in the objective criteria. In the ankle fractures study in 2 patients haematoma revisions and in 2 patients with the primary used oblique insertion of the nail a proximal fibula fracture occurred. In one case a spilt skin graft was needed. In no case infection of the bone was seen, in no case fracture or implant dislocation occurred. At re-examination 71% showed an excellent and 25% a good result. Only 3 Patients were classified as fair (1) or unsatisfactory; in 1 due to algodystrophia.

Conclusion: the minimal invasive stabilisation of pilon fractures with the XS nail and the absence of plates on the bone surface reduces significantly the healing problems and the rate of severe complications of pilon fractures. The unfavourable blood supply of the distal metaphysis and soft tissue damage still represent problems which

can require secondary bone grafting and local flaps but in no case osteomyelitis was seen. The Xs nail is also a new option for ankle stabilisation. It improves the stability and reduces the complication of ankle osteosynthesis due to the lack of implant under the skin on the bone surface and due to the higher biomechanical stability of intramedullary implants.

IL10

Overview lecture: patella fractures

V. Bühren[1]. [1]*BG Unfallklinik Murnau, Murnau, Germany*

Classically, the patella is caused by an impact trauma, such as falling on the bent knee or as part of a traffic accident as a "dashboard injury". The classification of patellar fractures depends on fracture history and location of the fracture. Most common is the AO classification. Undislocated longitudinal fractures, undislocated transverse fractures (up to 40° flexion no dislocation) and low dislocated distal fractures without joint involvement can be treated conservatively, if the yield lifting capacity of the knee has been preserved.

Indications for surgical treatment are:

- Fractures with dislocation of 2 mm
- Open fractures
- Comminuted fractures
- Undislocated fractures with reversed stretchability in the knee joint

For a long time the tension band was of choice for treatment of patellar fractures. The principle of tension band based on the conversion of tensile and bending forces in pressure forces, whereby a dynamic interfragmental compression is to be achieved. In simple transverse fractures, distal or fractures with up to 4 fragments the screw fixation is an option. The angular stable Patellaplate is now an adequate instrument for the supply of complex fractures. In biomechanical studies, the plate showed a significantly higher stability in comparison to the tension band. At our clinic so far 65 patients were treated with the Patellaplate supplied. In 19 patients still screws or cerclage were used additively. There are several ways to supply patella. Especially with problematic fractures as comminuted fractures or osteoporotic fractures the plate fixation is a good therapeutic option, since the plate has a high biomechanical stability and by the anatomical configuration allows a good reduction and restoration of the articular surface.

IL13

Todays' place of ExFix fracture management in primary care, definitive treatment and complication management in a developing health care environment

P.-D. Sîrbu[1]. [1]*Orthopaedics, Gr.T. Popa Medicine and Pharmacy University, Iasi, Iasi, Romania*

A history of ExFix fracture management starting with 1990 until today in a level 1 trauma center from Romania is presented.

The author enhances the use of ExFix initially only in open fractures and then for polytrauma, infected fractures or special fractures: pelvic fractures, distal radius fractures, pilon and tibial plateau fractures with 2 steps management.

Starting with the old Romanian Burghele external fixator, the author exhibits the widening of medical indications for ExFix treatment as well the progressive improvement of types and qualities of the external fixators, despite the managerial difficulties.

A new type of ExFix system developed by a Romanian orthopaedic surgeon is presented too.

Injury, Int. J. Care Injured (2016) **47**(S5), S39–S40

Contents lists available at SciVerse ScienceDirect

Injury

journal homepage: www.elsevier.com/locate/injury

Author index

*Page numbers for abstracts are followed by the abstract number(s) in parentheses. Abstract number in bold indicates presenter.